

Contents lists available at [Sjournals](http://Sjournals.com)



Journal homepage: [www.Sjournals.com](http://www.Sjournals.com)



**Short communication**

## **Parasites, haematology and morphological changes in tissues of a migratory *Bubulcus ibis***

**O.A. Adediran<sup>a,\*</sup>, A.J. Jubril<sup>b</sup>, E.C. Uwalaka<sup>a</sup>, T.A. Jarikre<sup>b</sup>**

<sup>a</sup>*Department of Veterinary Microbiology and Parasitology, University of Ibadan, Nigeria.*

<sup>b</sup>*Department of Veterinary Pathology, University of Ibadan, Nigeria.*

*\*Corresponding author; Department of Veterinary Microbiology and Parasitology, University of Ibadan, Nigeria.*

### ARTICLE INFO

*Article history,*

Received 21 April 2015

Accepted 22 May 2015

Available online 29 May 2015

*Keywords,*

Cattle egret

Migratory birds

Parasites

Histopathological lesions

Haematology

### ABSTRACT

Cattle egret having been used in the control of flies and other insects on cattle also has been implicated in the transmission of different diseases including parasites. This migratory bird was studied to see the type of parasites it carries and its hematologic status as an indicator of health. The bird was found, caught and brought to the Department of Veterinary Microbiology and Parasitology of the University for Routine Helminth Ova and Protozoan cyst screening using parasitological techniques. Also, tissues were harvested for histopathological examination. Haematologic and clinical chemistry analysis was carried out. Clinically, the bird showed emaciation, dissipation and inability to fly. No helminth ova or protozoan cysts were recovered from faecal examination, however, *Heterakis gallinarum* and *Echinostoma* species were recovered as adults from the posterior guts. Grossly, most of the organs were within the normal textural and conformational limits, except for the liver, which showed moderate congestion and enlargement. Microscopically, the liver revealed congestion of the venules, moderate distortion of the hepatic plates, swollen hepatocytes and obliteration of the sinusoid. The presence of the nematode, *Heterakis gallinarum*, has an implication on disease transmission to domestic birds while *Echinostoma* species are zoonotic thus humans can be predisposed to infection from these migratory birds. The haematology report is an indication of

---

poor health due to its lower margin of normal values. An understanding of the parasites and lesions in the bird would aid evaluating the health status of the migratory bird and the public health implication of its presence.

© 2015 Sjournals. All rights reserved.

---

## 1. Introduction

*Bubulcus ibis* (Cattle Egret) is of the Family *Ardeidae* (Hérons and Egrets), Order *Ciconiiformes* (Storks, Herons and Ibises), and Class *Aves* (Birds) (Sheldon, 1987). Cattle egrets are white heron-like birds of about 18–22 inches long and a 32-38 inch wingspan. They have a characteristic thick neck and long sharp bill, which is black in juveniles and yellow in adults (Ivory, 2012) (fig. 1.). The *Ardeidae* differ from other *Ciconiiformes* such as the storks and ibises in having a long, spear like bill, a pectinate middle toe claw, a generally more slender body with a long neck, and an elaborate variation in display feathers on the head, neck, and back (Sibley and Ahlquist, 1972).

Cattle egrets are now widespread in distribution and are classified as a species of Least Concern by the International Union of Conservation of Nature (IUCN). They are free range migratory birds. The cattle egret lives alongside large grazing herbivores such as cattle, zebra, water buffalo, bison, wildebeest and small ruminants. *B. ibis* feeds on a wide range of prey, particularly insects, moths, spiders, and frogs, as well as earthworms, most of which are involved in parasitic life cycles (Fogarty and Hetrick, 1973; Seedikkoya et al., 2007). The role of this bird in management of insect pests in different agro-ecosystems has also been reported by (Chaturvedi, 1993; Yadav and Tindall, 2000).

Economic importance of Cattle egret is immense to the public and livestock industry. Cattle egret reduces the numbers of flies which irritate cattle, control dipterous pests of cattle (Blakar, 1969). Cattle egrets have also been implicated in the dispersal of *Amblyomma* (Siegfried, 1972; Ali, 2002), and thus spread of heart water. Egrets and other herons are reservoir of Japanese encephalitis virus infection, a mosquito-borne zoonotic viral disease that affects horses, donkeys, pigs and humans. Infected birds are asymptomatic carriers and considered as “amplifier hosts”, in the transmission cycle, while mammals are “dead end” hosts (Dutta, 2011). Threats of avian influenza to human health have warranted widespread surveillance of African migratory, feral and resident territorial birds<sup>13</sup>. The African continent sustains a high diversity of migratory and non-migratory bird species, many of which live in close association with humans, swine and poultry. Myriad of parasite species have been identified from free-ranging wild birds (Permin et al., 1999). The purpose of this study is to examine the type of parasite seen and the hematologic data of the wild bird to access the health status and to evaluate for evidence of systemic disease.

## 2. Materials and methods

The cattle egret (*Bubulcus ibis*) was found, caught and brought to the Department of Veterinary Microbiology and Parasitology by a member of the community.

The bird was examined ante mortem, bled by venupuncture, sacrificed and subjected to necropsy and histopathological evaluation. Fresh gut content were routinely screened for helminth and faecal samples examined for ova and protozoan cyst using standard parasitological technique as described by Khin-Khin et al (Khin-khin, 2007). Samples from different organs were immediately fixed in 10% neutral formalin and then routinely processed for paraffin embedding. Sections of thickness 4 µm were stained with hematoxylin and eosin and examined microscopically.

For haematology and clinical chemistry, 2 ml blood was collected from the jugular vein of the bird. The Packed cell volume (PCV) was determined by the micro heamatocrit method. The Haemoglobin (Hb) concentration was measured by spectrophotometry using the cyanmethhaemoglobin method. Readings were taken at 450 nm. The Red blood count (RBC) and Platelet (PT) counts were estimated using improved Hawksley haemocytometer. These are the mean corpuscular haemoglobin (MCH), the mean corpuscular volume (MCV) and the mean corpuscular haemoglobin concentration (MCHC). These indices are calculated from the values of PCV, RBC, and Hb.

Total protein, an estimate of the protein content, was measured from the plasma using a clinical refractometer. Total white blood cell count (WBC) was calculated using methods described by Jain et al (Jain, 1986). Aspartate amino transferase (AST) and Alanine amino transferase (ALT) activities were determined using spectrophotometric methods as described by Rej and Hoder (Rej and Hoder, 1983).

### 3. Results

The bird was found to have features different from the indigenous cattle egret and was identified to be migratory. Clinically, the bird showed emaciation, dissipation and inability to fly. No helminth ova or protozoan cysts were recovered from faecal examination. Two medium sized nematodes measuring 3cm and 3.5cm in length was found in the posterior intestine. The worm had cuticular striations along its length with a pointed tail and caudal papillae. This was identified as *Heterakis gallinarum*. A trematode measuring 1cm by 0.4 cm was seen in the posterior gut. The presence of a raised collar of spines around the oral sucker distinguishes this worm. This was identified as *Echinostoma* species.

Grossly, most of the organs were within the normal textural and conformational limits, except for the liver, which showed moderate congestion and enlargement. Microscopically, the liver revealed congestion of the periportal and central venules, moderate distortion of the hepatic plates, swollen hepatocytes and obliteration of the sinusoids. There were numerous inflammatory cells (heterophils, macrophages & lymphocytes) around the periportal areas, remarkable bile ductular hyperplasia, fibrosis and multifocal necrosis of hepatocytes (Fig. 2. 3. 4.).

Results for PCV (32%), Hb (10.5 g/dL), RBC count ( $4.12 \times 10^6/\mu\text{L}$ ), MCH (77.6fl), MCHC (32.8g/dl), Total protein (3.2g/dl), WBC count (7250cells/dl), absolute differential white blood cell count (heterophils, 3842 cells/dl , lymphocytes 1957 cells/dl, eosiniphils 798 cells/dl, basophil 362,cells/dl, monocyte 290, cells/dl).

The AST value of 422 U/l, the ALT value of 60 U/l and ALP of 361U/l were determined in the clinical chemistry analysis of the bird, the values reported are within the reference range for normal.



Fig. 1. Picture of the cattle egret.

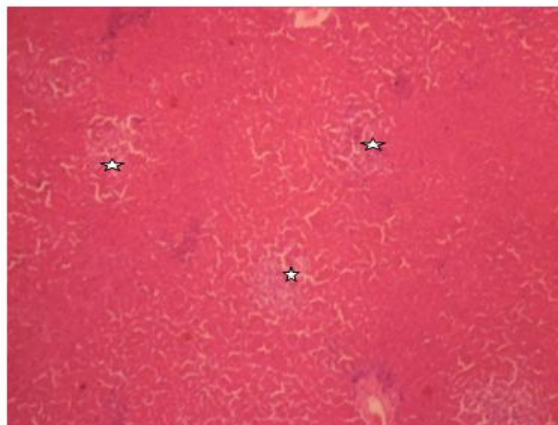
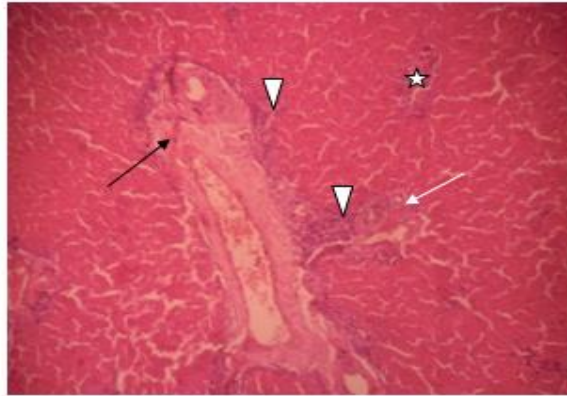
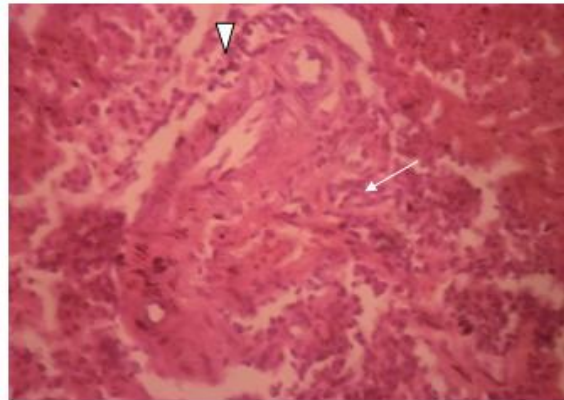


Fig. 2. Multiple foci of necrosis of hepatocytes (star)  $\times 100$  H&E.



**Fig. 3.** Perivascularitis (arrow head), Bile ductular hyperplasia (white arrow), fibrosis in a portal area (black arrow) and a focus necrosis (star)  $\times 100$  H&E.



**Fig. 4.** Marked Perivascularitis (arrow head) and fibrosis in a portal area (white arrow)  $\times 400$  H&E.

#### 4. Discussion

In nature, parasites such as nematode have been responsible for regular population cycles in the subspecies of migratory birds. *Heterakis gallinarum* is one of the most frequently diagnosed nematodes within the digestive tract of galliform birds (Lund et al., 1970). Infection with *H. gallinarum* is generally subclinical, but the parasite may also function as a vector for *Histomonas meleagridis*, which is known to induce severe pathological lesions and high mortality rates in susceptible aviary hosts (Smith and Bush, 1978; Glick, 1960). Parasites like trematode such as *Pegosomum* sp have induced severe lesions in *B. ibis*, and have been associated with natural death in free-living cattle egret (Esquenet and De Herdt, 2003).

Although many studies have investigated the prevalence of *H. gallinarum* in the chicken (Anderson and May, 1991; Lund and Chute, 1974) and the induction of pathological lesions after *H. gallinarum* infection (Kaushik and Deorani, 1969; Johnson, 1920), little or no information is available on the presence of this parasite in *B. ibis*. The widespread presence of *B. ibis* and the isolation of *H. gallinarum* which transmits Blackhead disease caused by *Histomonas meleagridis* has serious implication for the local domestic poultry especially turkey as the migratory birds may continue to serve as transmission source in the environment. Relationships between wild birds, livestock, humans and diseases vary in ecological complexity and health consequences (Friend, 2006). Some disease pathogenesis involves pathogens that cause morbidity or mortality in specific bird species, whereas others rely on multiple species of apparently healthy birds to spread pathogens. Additionally, migratory birds play a significant role in the re-emergence of diseases, especially disease of public health significance across continents such as Asia, Russia, the Middle East, parts of Europe, and Africa having poor screening and quarantine procedures especially for air-borne migratory birds. Hematocrits of migrating healthy birds may be significantly greater than

those in captivity and high altitude is known to increase the production of red blood cells due to the greater demand for efficient oxygen extraction from air. Haemoconcentration from dehydration may also occur in migrating birds (Carpenter, 1975; Perry et al., 1986) because of relative reduced intake of water. The lower limit of normal value of the PCV in the bird however, is contrary to this and suggests that the bird might not be healthy.

The haematology and clinical chemistry values fall within range of normal counts for egret but towards the lower limit for normal when compared to the reference range. (Elliott et al., 1974; Riddell and Gajadhar, 1988). The relative differential white cell counts also agree with those previously reported (Russo et al., 1986; Hernandez et al., 1990). However, it is difficult, if not impossible, to measure normal white blood cell counts accurately in egrets since these birds are unavoidably stressed when handled and especially when captured in the wild and migration is also a source of stress to migratory birds such as the egret <sup>41</sup> ACTH and corticosteroids have been shown to be elevated during periods of stress in birds (Wolford and Ringer, 1962).

## 5. Conclusion

Migratory birds such as the egret we have studied should not be allowed near poultry farms because they could act as vectors of infectious agents. Man could also be at risk of infection with zoonotic diseases from these birds if allowed in close contact. The authors declare that there are no competing interests.

## References

- Abdo, W., Sultan, K., 2013. Histopathological findings of the kidney Trematoda Paratanaisia spp. (Digenea: Eucotylidae) in cattle egret (*Bubulcus ibis*). *Rev. Bras. Parasitol. Vet.*, Jaboticabal. 22(2), 312-313.
- Abdu, P.A., 2010. Qualitative risk assessment on the transmission of HPAI (H5N1) virus from backyard and medium-scale commercial farms to household free-range poultry in Nigeria. Pro-poor HPAI Risk Reduction Project. Africa/Indonesia Team Working Paper. ILRI/IFPRI/RVC.
- Acetate on the white blood cell counts of 2 weeks - old chickens. *Poult. Sci.* 40, 1537 – 1539.
- Ali, N., 2002. The book of Indian birds. 13th ed. Bombay Natural History Society & Oxford University Press.
- Anderson, R.M., May, R.M., 1991. Infectious diseases of humans: Dynamics and control. Oxford University Press, Oxford.
- Bell, D.J., Freeman, M.B., 1971. The blood of avian species. Physiology and biochemistry of the domestic fowl. 2nd Edn. Churchill, London.
- Blakar, B.R., 1969. Behavior of the Cattle egret. *Ostrich.* 40(3), 75-129.
- Carpenter, F.L., 1975. Bird hematocrits: Effects of high altitude and strength of flight. *Comp. Biochem. Physiol.* 50, 415-417.
- Chaturvedi, N., 1993. Dietary of the Cattle egret *Bubulcus ibis coromandus* (Boddaert). *J. Bombay. Nat. Hist. Soc.* 90(1), 90.
- Dutta, P., Khan, S.A., Khan, A.M., Borah, J., Sarmah, C.K., Mahanta, J., 2011. The effect of insecticide-treated mosquito nets (ITMNs) on Japanese encephalitis virus seroconversion in pigs and humans. *Am. J. Trop. Med. Hyg.* 84, 466-472.
- Elliott, R.H., Smith, E.E., Bush, M., 1974. Preliminary report on hematology of birds of prey. *J. Zoo. Anita. Med.* 5, 11-16.
- Esquenet, C., De Herdt, P., De Bosschere, H., Ronsmans, S., Ducatelle, R., Van Erum, J., 2003. An outbreak of histomoniasis in free-range layer hens. *Avian. Pathol.* 32, 305-308.
- Fogarty, M.J., Hetrick, W.M., 1973. Summer foods of cattle egrets in north central Florida. *The Auk.* 90(2), 268–280.
- Friend, M., 2006. Disease emergence and resurgence: the wildlife-human connection. U.S. Geological Survey Circular No. 1285. Reston, VA. 400.
- Gessaman, J.A., Johnson, J.A., Hoffman, S.W., 1986. Hematocrits and erythrocyte numbers for Cooper's and sharp-shinned hawks. *Condor.* 88, 95-96.
- Gibbs, B.J., 1962. The occurrence of the protozoan parasite *Histomonas meleagridis* in the adults and eggs of the cecal worm *Heterakis gallinae*. *J. Proto.* 9, 288-293.
- Glick, B., 1960. The effect of bovine growth hormone desoxycorticosterone, and cortisone



- Hernandez, M., Martin, S., Fores, P., 1990. Clinical hematology and blood chemistry values for the common buzzard (*Buteo buteo*). *J. Raptor. Res.* 24(4), 113-119. 41. Maxwell MH. Avian blood leucocyte responses to stress. *World. Poult. Sci.* 1993; 49, 34-43.
- Ivory, A., 2013. *Bubulcus ibis*. *Animal Diversity Web* 2000 (Accessed November 9th, [http://animaldiversity.ummz.umich.edu/accounts/2012/11/9/Bubulcus\\_ibis/Hudson](http://animaldiversity.ummz.umich.edu/accounts/2012/11/9/Bubulcus_ibis/Hudson)).
- Jain, N.C., 1986. Schalm's veterinary hematology fourth edition, Lea and Febiger. Philadelphia.
- Johnson, J., 1920. The life cycle of *Echinostoma revolutum* (Froelich). *Univ. California. Public.* 19, 335-388.
- Kaushik, R.K., Deorani, V.P., 1969. Studies on tissue responses in primary and subsequent infections with *Heterakis gallinae* in chickens and on the process of formation of caecal nodules. *J. Helminthol.* 43, 69-78.
- Khin-khin, L., 2007. Prevalence of *Cryptosporidia*, *giardia*, and other gastrointestinal parasites of dairy calves in Mandalay, Myanmar. MPh Thesis. Chuang Mai University and Frere Universiat Berlin.
- Kurt, M., Acici, M., 2008. Cross-sectional survey on helminth infections of chickens in the Samsun region, Turkey. *Deutsche Tiera" rztliche Wochenschrift.* 115, 239-242.
- Lund, E.E., Chute, A.M., 1974. The reproductive potential of *Heterakis gallinarum* in various species of Galliform birds: implications for survival of *H. Gallinarum* and *Histomonas Meleagridis* to recent times. *Int. J. Parasitol.* 4, 455-461.
- Lund, E.E., Chute, A.M., Myers, S.L., 1970. Performance in chickens and turkeys of chicken-adapted *Heterakis Gallinarum*. *J. Helmint.* 44, 97-106.
- Maurer, V., Amsler, Z., Perler, E., Heckendorn, F., 2009. Poultry litter as a source of gastrointestinal helminth infections. *Vet. Parasitol.* 161, 255 -260.
- Mungube, E.O., Bauni, S.M., Tenhagen, B.A., Wamae, L.W., Nzioka, S.M., Muhammed, L., Nginyi, J.M., 2008. Prevalence of parasites of the local scavenging chickens in a selected semi-arid zone of Eastern Kenya. *Trop. Anim. Health. Prod.* 40, 101\_109.
- Permin, A., Bisgaard, M., Frandsen, F., Pearman, M., Kold, J., Nansen, P., 1999. Prevalence of gastrointestinal helminths in different poultry production systems. *Br. Poult. Sci.* 40, 439-44.
- Perry, M.C., Obrecht, H.H., Williams, B.K., Kuenzel, W.J., 1986. Blood chemistry and hematocrit of captive and wild canvasbacks. *Wildl. Manage.* 50, 435-441.
- Rej, R., Hoder, M., 1983. Aspartate transaminase. In: *Methods of enzymatic analysis*. 3rd ed. (Bergmeyer HU, Bergmeyer J and Grassl M, Eds). WeinheinVerlag-Chemie. 3, 416-433.
- Riddell, C., Gajadhar, A., 1988. Cecal and hepatic granulomas in chickens associated with *Heterakis Gallinarum* infection. *Avian. Dis.* 32, 836-838.
- Russo, E.A., Mgntee, L., Applegate, L., Baker, J.S., 1986. Comparison of two methods for determination of white blood cell counts in macaws. *JAVMA.* 189, 1013-1016.
- Seedikkoya, K., Azeez, P.A., Abdul Shukkur, E.A., 2007. Cattle egret as a biocontrol agent. *Zoos' Print Journal.* 22 (10), 2864-2866.
- Sheldon, F.H., 1987. Phylogeny of herons estimated from DNA-DNA hybridization data. *The Auk.* 104(1), 97-108.
- Sibley, C.G., Ahlquist, J.E., 1972. A comparative study of the egg white proteins of non-passerine birds. *Yale Univ. Peabody. Mus. Nat. Hist. Bull.* 39.
- Siegfried, W.R., 1971. The food of the cattle Egret. *J. App. Ecol.* 8(2), 447-468.
- Siegfried, W.R., 1972. Aspects of feeding ecology of cattle egret in South Africa. *J. Anim. Ecol.* 41(71-78).
- Smith, E.E., Bush, M., 1978. Haematologic parameters on various species of *Strigiformes* and *Falconiformes*. *J. Wildl. Dis.* 14, 447-450.
- Springer, W.T., Johnson, J., Reid, W.M., 1969. Transmission of histomoniasis with male *Heterakis Gallinarum* (Nematoda). *Parasit.* 59, 401-405.
- Wolford, J.H., Ringer, R.K., 1962. Adrenal eight, adrenal ascorbic acid, and adrenalcholesterol and differential leukocyte counts as physiological indicators of stressor agents in laying hens. *Poult. Sci.* 41, 1521-1529.
- Yadav, E.S., Tindall, B.D.N., 2000. All India network project on agricultural ornithology: Annual report. *Gujara. Agr. Univ. Anand.* 1-14.