

Contents lists available at Sjournals

Journal homepage: www.Sjournals.com**Original article****Chlorpyrifos-induced testicular damage in rats: The effect of glutathione antioxidant****E.E. Elsharkawy^{a,*}, D. Yahia^b, N.A. El-Nisr^c**^{a,b}Departement of Fronsic Med. and Toxicology fac. of Vet. Med. Assuit University., Egypt^cAnimal Health Institute of Research- Egypt^{*}Corresponding author; Departement of Fronsic Med. and Toxicology fac. of vet .med. Assuit University, Egypt

ARTICLE INFO

ABSTRACT

Article history:

Received 13 May 2012

Accepted 15 June 2012

Available online 06 July 2012

Keywords:

Chlorpyrifos

Testosterone

Alkaline phosphatase

Oxidative stress

Spermatogenesis

This study investigated the induction of oxidative stress in the testis of adult rat exposed to Chlorpyrifos (CPF). CPF was administered orally, in a dose of 30 mg/kg body weight to male rats for 90 days/ twice/ weekly. Co- administration of water soluble non enzymatic antioxidant glutathione (GSH) was given in a dose of 100 mg/kg body weight, oral, for the same period. Another two groups of male rats were administered GSH and corn oil, respectively. The activities of superoxide dismutase and glutathione reductase were decreased while the levels of lipid peroxidation were increased in the testicular tissues of the exposed animals. Testosterone hormone level in the serum was significantly decreased. The decrease in the histochemical determination of testicular alkaline phosphatase was observed in CPF-treated rats. A significant decrease in all stages of spermatogenesis in the seminiferous tubules was recorded in the exposed animals. Co-administration of GSH restored these parameters.

© 2012 Sjournals. All rights reserved.

1. Introduction

Occupational exposure to pesticides is becoming a common and increasingly alarming worldwide phenomenon. Approximately 3 million acute poisonings and 220,000 deaths from pesticide exposure have been reported annually (Marrs 1993; USDA 1994; Yasmashita et al., 1997). The health effects cause by this occupational exposure are enormous. The widespread use of organophosphorus compounds (OP) and the high rates of food contamination could lead to humans, animals, and birds being exposed to high levels of this pesticidal chemical

(Suresh Babu et al., 2006). Chlorpyrifos (CPF), O,O-diethyl-O- (3,5,6-trichloro-2-pyridinyl) phosphorothioate, is classified as a moderately hazardous, Class II insecticide by the WHO, (1997). It belongs to the phosphorothioate class of insecticides. Its acute toxicity varies according to the species and route of exposure; acute oral LD50 for male rats is estimated to be 80 mg/kg bodyweight (Karanth et al., 2004). The chief mechanism of action of OP pesticides occurs by the inhibition of neuronal cholinesterase activity, a key enzyme that is involved in neurotransmission (Richardson et al., 1993). Pesticides are known to produce oxidative stress, and extensive data suggest that oxygen free radical formation can be a major contributor to the toxicity of pesticides [Lodovici et al., 1994; Bagchi et al., 2002]. Many insecticides are hydrophobic molecules that bind extensively to biological membranes, especially phospholipid bilayers and they may damage the membranes by inducing lipid peroxidation (Lee et al., 1991). Some OP pesticides have also been reported to affect the reproductive system (Farag et al., 2000). Chlorpyrifos can induce adverse effects on reproductive performance; showed fetotoxic and teratogenic effects at a maternal dose of 25 mg/kg-d, a dose that also produced maternal toxicity (Farag et al., 2003). Exposure to CPF poses the greatest problem to pregnant women and small children, with evidence of neurophysiologic effects in humans. Indoor spraying of CPF may pose a considerable risk to human health especially to children (Gurunathan and Bukowske., 1998; Qiao et al., 2003). Therefore, the relationship between maternal CPF exposure and birth defects has been controversial despite the importance to public health and concern over prenatal exposure (Tian et al., 2005). Antioxidants have a number of biological activities, including immune stimulation and alteration of the metabolic activities of carcinogens. These vitamins can also prevent genetic changes by inhibiting the DNA damage induced by reactive oxygen metabolites (Verma et al., 2007). Glutathione (GSH), the major water-soluble antioxidant, is known to protect cellular membranes and lipoproteins from peroxidation (Rana et al., 2002). The aim of this study was to determine the effect of subchronic CPF exposure on the reproductive system of male rats and to assess whether these effects can be ameliorated by co-treatment with GSH.

2. Materials and methods

2.1. Chemicals

Chlorpyrifos of purity 96.5% (Technical Grade) and glutathione 100% (pure powdered form) were purchased from Sigma Chemicals Co. (St. Louis, USA). All other chemicals were of the highest grade available commercially.

2.2. Animals

Sexually mature male Sprague Dawley rats (weighing approximately 200–250 g), obtained from the Laboratory Animals House, Assiut University, and were used. The animals were housed in plastic cages, fed a standard laboratory diet and water *ad libitum*, exposed to a 12 h light/dark cycle, and maintained at a laboratory temperature of 24 ± 2 °C. The animals were quarantined for 10 days before beginning the experiments. All rats were handled in accordance with the standard guide for the care and use of laboratory animals.

2.3. Animal treatment schedule

Animals were randomly divided into four groups of ten animals each. Animals in CPF-treated group: were given twice/ weekly a dose of CPF alone (30 mg/kg body weight, oral) for 90 days. Animals in CPF plus GSH-treated group: were simultaneously given glutathione as an aqueous solution at a dose of (100 mg/kg body weight, oral); twice/ weekly, during the 90 days and exposed to the CPF at the previous dose. Animals in GSH-treated group: were given aqueous solution of glutathione alone; twice/ weekly for 90 days. Control group: were given only standard pellet diet and corn oil.

2.4. Oxidative status in testicular tissues

2.4.1. Superoxide dismutase

Superoxide dismutase (EC.1.15.1.1) was assayed by the method of Marklund and Marklund, (1974). Briefly, the assay mixture contained 2.4 mL of 50 mM Tris HCl buffer containing 1 mM EDTA (pH 7.6), 300 μ L of 0.2 mM pyrogallol and 300 μ L enzyme source. The increase in absorbance was measured immediately at 420 nm against a

blank containing all the components except the enzyme and pyrogallol at 10 s intervals for 3 min on a Systronics Spectrophotometer.

2.4.2. Glutathione reductase

Glutathione reductase (EC. 1.6.4.2) was assayed by the method of Carlberg and Mannervik, (1975). Briefly, the assay mixture contained 1.75 mL phosphate buffer (100 mM, pH 7.6), 100 mL of 200 mM NADPH, 100 mL of 10 mM EDTA, 50 mL of 20 mM oxidised glutathione, and 50 mL enzyme source. Disappearance of NADPH was measured immediately at 340 nm against a blank containing all the components except the enzyme at 10 s intervals for 3 min on a Systronics Spectrophotometer.

2.4.3. Lipid peroxidation

A breakdown product of lipid peroxidation, thiobarbituric acid reactive substance (TBARS), was measured by the method of Buege and Aust, (1978). Briefly, the stock solution contained equal volumes of 15% (w/v) trichloroacetic acid in 0.25 N hydrochloric acid and 0.37% (w/v) 2-thiobarbituric acid in 0.25 N hydrochloric acid. One volume of the test sample and two volumes of stock reagent were mixed in a screw-capped centrifuge tube, vortexed, and heated for 15 min in a boiling water bath. After cooling on ice, the precipitate was removed by centrifugation at 1000 g for 15 min, and absorbance of the supernatant was measured at 532 nm against a blank containing all the reagents except test sample. A standard curve was constructed extrapolating the amount of the commercially bought product malondialdehyde to the measured absorbance.

2.5. Testosterone hormone assay

Serum testosterone levels were measured by RIA following extraction with diethyl ether as described previously Murono et al, (1989).

2.6. Histochemical study

Histochemical determination of alkaline phosphatase activity in frozen sections of testicular tissues was demonstrated according to EL-Aser et al., (1977).

2.7. Quantitative analysis of seminiferous epithelial cycle and leydig cells

The identification of the different stages of seminiferous epithelial cycle (50 seminiferous tubules for each animal) was based on the morphological changes of the germ cell nuclei and the local arrangement of the spermatids (Franca et al., 1995). The number of Leydig cells/mm² (unit area) was counted using the square grid (area/mm²) at 1000X magnification and 35 unit areas were counted. The nuclear volume of the Leydig cells was performed using ocular micrometer at 1000X magnification. The total numbers of 300 nuclei were measured /animal. The measurement was carried out by concerning rounded nuclei of Leydig cells, where the formula of the sphere was applied as $(V=4/3 \pi R^3)$, where R=nuclear diameter/2.

2.8. Histopathology

For histopathological examination, the testicular tissues were dissected and the tissue samples were fixed in Zenker solution for 24 h, processed by using a graded ethanol series, and embedded in paraffin. The paraffin sections were cut into 5 ml thick slices and stained with hematoxylin and eosin for light microscopic examination.

2.9. Statistical analyses

Data were analyzed using one way analysis of variance (ANOVA) followed by Duncan's multiple range test. All data were expressed as mean \pm SD for four experimental and four control animals/dose. $P > 0.05$ was considered significant compared to control.

3. Results

3.1. Oxidative status in testicular tissues

The activities of superoxide dismutase and glutathione reductase of the testicular tissues showed a significant ($p < 0.05$) decrease while the levels of lipid peroxidation increased in both CPF-treated and GSH plus CPF-treated

rats in comparison with the control. There is a significant ($p < 0.05$) difference between the CPF-treated group and GSH plus CPF-treated rats (Table 1).

3.2. Measurement of testosterone

The control and GSH-treated rats had equivalent of testosterone levels at the end of the 90 day, but the CPF-treated and GSH plus CPF-treated rats had significantly ($p < 0.05$) lower serum testosterone levels than the control rats (Table 2). However, the GSH plus CPF-treated rats don't differ significantly ($p < 0.05$) from the CPF-treated rats in terms of serum testosterone levels (Table 2).

Table 1

The effect of the CPF on the oxidative status in the control and exposed groups of rats.

	Total lipid peroxide (nmol/mg protein)	Superoxide Dismutase (nmol/mg protein)	Glutathione reductase (nmol/mg protein)
CPF	0.29 ± 0.07 [*]	0.36 ± 0.02 [*]	0.59 ± 0.14 [*]
CPF+GSH	0.10 ± 0.03 ^{*a}	0.43 ± 0.02 ^{*a}	1.07 ± 0.04 ^{*a}
GSH	0.14 ± 0.01 ^{ab}	1.22 ± 0.11 ^{ab}	1.14 ± 0.03 ^{ab}
Control	0.17 ± 0.02	0.98 ± 0.14	1.72 ± 0.07

Values are expressed as means ± SE (n=15). ^{*}Significance at $P < 0.05$. ^aComparison of control. ^{ab}Significance at $P < 0.05$. ^aComparison of CPF. ^bSignificance at $P < 0.05$. ^aComparison of CPF+GSH

Table 2

The effect of the CPF on the testosterone hormone level in exposed and control groups of rats.

	CPF	CPF+GSH	GSH	Control
Testosterone (µg/dl)	2.86 ± 0.04 ^{*b}	2.94 ± 0.05 ^{*a}	3.86 ± 0.07 ^{ab}	3.92 ± 0.09

Values are expressed as means ± SE (n=15). ^{*}Significance at $P < 0.05$. ^aComparison of control. ^{ab}Significance at $P < 0.05$. ^aComparison of CPF. ^bSignificance at $P < 0.05$. ^aComparison of CPF+GSH

3.3. Histochemical study of alkaline phosphatase in testicular tissues

Figure 2 shows that alkaline phosphatase activities in rat testis were strongest in the peritubular compartment and in occasional interstitial cells. There was also strong reactivity in the vascular endothelium in control group (Fig.2.a). After 90 days of CPF exposure, the intensity of staining indicates that a decrease of testicular alkaline phosphatase activity in CPF-treated rats and GSH plus CPF-treated rats (Fig.2. b,c) in comparison of control.

3.4. Quantitative analysis of seminiferous epithelial cycle and Leydig cells

The quantitative results of the seminiferous tubules cycles are presented in Table (3). There was a significant decrease in the mean number of different germ cell types in all stages of the seminiferous tubules in both exposed groups versus those of controls. The mean number and nuclear volume of Leydig cells were significantly decreased as shown in Table (4).

3.5. Histopathology

The seminiferous tubules of the GSH-treated group and control rats were structurally normal, and they were found appeared to be uniform in size and shape. They were lined by regularly arranged rows of spermatogenic cells at different stages of maturation (Fig. 1A). In contrast, after 90 days of CPF-exposure, there were fewer spermatogenic cells in some of the seminiferous tubules which dissociated from each other (Fig.1B), necrosis in some seminiferous tubules accompanied with edema in the interstitial tissue (Fig. 1C) and the testicular blood vessels were engorged with blood and had very thick walls (Fig. 1D) associated with connective tissue proliferation (Fig. 1E). Moreover, in the GSH plus CPF-treated group, the seminiferous tubules had more or less normal

structure with mild changes in spermatogenic cells accompanied with mild edema in the interstitial tissues (Fig. 1F).

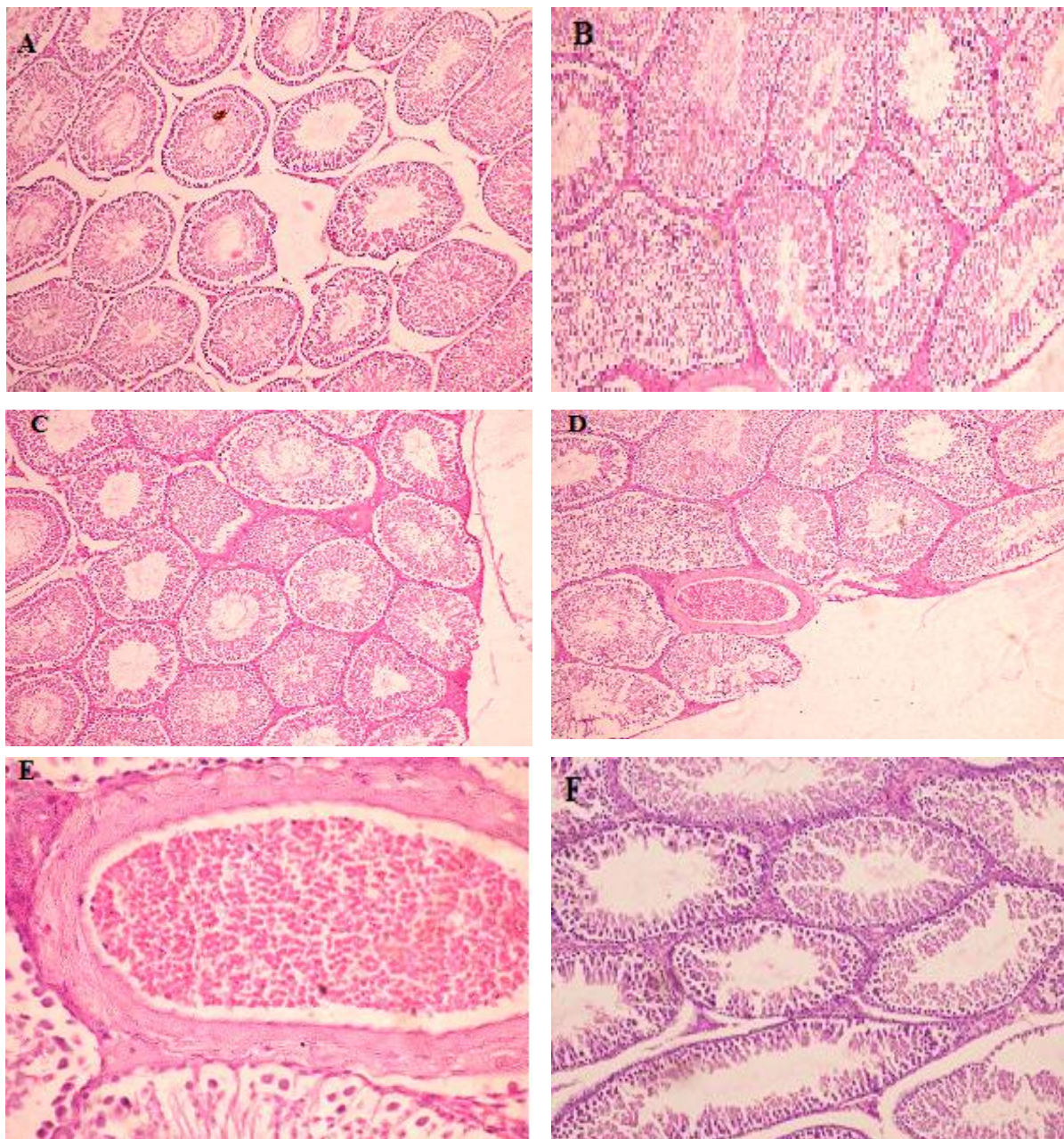


Fig. 1. (A. Testes of CPF- treated groups showed seminiferous tubule dissociated from each other with decreasing in spermatogenic cells H&E X10. (B. Interstitial edemas present among the seminiferous tubule from the same group H&E X25. (C. Sever congestion of the testicular blood vessel which has thick wall H&E X10. (D Thick wall and congested blood vessel associated with proliferating connective tissue H&E X40.(F. Testes of GSH plus CPF- treated group showed seminiferous tubules had mild changes in spermatogenic cells accompanied with mild edema in the interstitial tissues H&E X10.

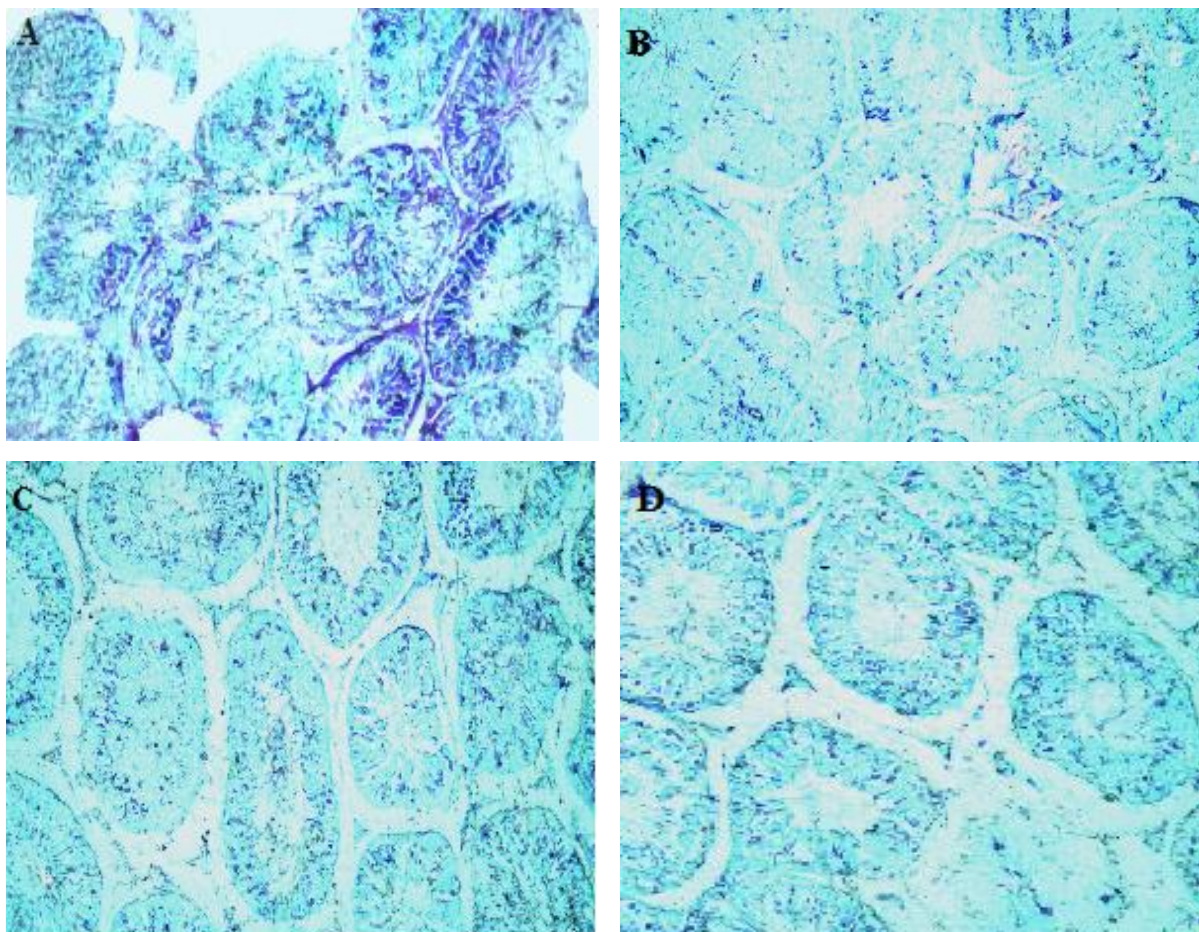


Fig. 2. Section of testis stained for alkaline phosphates showed (A) The dark deposits indicating enzyme activity (arrowheads) are limited to selected interstitial cells and peritubular elements in control group (X 40). (B) Seminiferous tubules with faint staining inside the tubular epithelium and interstitial space indicating weak enzyme reaction in CPF -treated group (X 40). (C) Seminiferous tubules with moderate staining inside the tubular epithelium and interstitial space indicating improve in enzyme reaction in CPF plus GSH - treated group (X 40).

4. Discussion

A role of ROS in infertility due to defective sperm function has been reported (Aitken and Clarkson, 1987; Aitken et al., 1989; Peltola et al., 1994). The excessive generation of ROS has been shown to cause peroxidative damage to the plasma membrane, which leads to impaired sperm function (Kobayashi et al., 1991). Superoxide dismutase depletion is thought to be associated with sperm immobility (Kobayashi et al., 1991). Testicular production of free radicals and activation of the antioxidant defense system have been reported after exposure to toxic chemicals (Aitken et al., 1989 and Peltola et al., 1994) and the epididymal production of free radicals and function of the antioxidant defense system require further studies. Previous studies have shown that lindane induces oxidative stress in the testis as well as in the epididymis and epididymal sperm of adult rats (Chitra et al., 2001 and Sujatha et al., 2001). In the present study, we have sought to determine the effect of CPF on the testicular antioxidant system of adult rats by measuring the antioxidant enzymes and lipid peroxidation in various regions of the testicular tissues. Our results revealed that a pronounced increase in the products of lipid peroxidation while a significant decrease was obtained in the levels of superoxide dismutase and glutathione reductase. CPF is known to generate oxidative stress, induce lipid peroxidation, and cause depletion of reduced glutathione (GSH), increase in oxidized glutathione (GSSG), and decrease in the ratio of GSH/GSSG in rat erythrocytes and tissues (Gultekin et al., 2001 ; Verma and Srivastava, 2001, 2003).

Table 3

The effect of the CPF on The different stages of the somniferousepithelial cycle in control and exposed groups of rats.

	Sertoli cells	Spermatogonia		Primary spermatocyt	Secondary spermatocyt	Spermatids		Spermatozoa
		Type A	Type B			Round	Elongated	
CPF	1.52±0.16*	17.5±1.5*	3.7± 2.4*	33.12±1.7*	4.5±0.22*	35.6±1.87*	8.5±0.45*	10.4±0.77*
CPF+GSH	1.0±0.11 ^a	13.8±1.0 ^a	3.0± 5.8*	28.6±1.4*	3.6±0.24*	28.6±1.47 ^a	8.5±0.60*	8.78±0.66 ^a
GSH	3.74±0.10	22.5±1.1	8.7± 2.8	43.73±1.3	7.6±0.21	44.82±2.78	9.0±0.35	11.99±0.54
Control	3.54±0.13	23.6±1.2	8.8± 2.6	46.76±1.6	7.2±0.23	46.88±2.48	9.4±0.55	12.56±0.62

Values are expressed as means ± SE (n=15). *Significance at P < 0.05. ^aComparison of control. ^aSignificance at P < 0.05. ^aComparison of CPF.

^bSignificance at P < 0.05. ^aComparison of CPF+GSH

Table 4

The effect of the CPF on Mean of Leydig cells number and nuclear volume in exposed and control group of rats

	Mean number of Leydig cells	Mean nuclear volume of Leydig cells (µm ³)
CPF	1.47 ± 0.1*	1.61 ± 0.2*
CPF +GSH	4.54 ± 0.5 ^a	8.68 ± 0.3 ^a
GSH	7.17 ± 0.3 ^{ab}	12.01±0.4 ^{ab}
Control	7.28 ± 0.5	11.90 ± 0.5

Values are expressed as means ± SE (n=15). *Significance at P < 0.05. ^aComparison of control. ^aSignificance at P < 0.05.

^aComparison of CPF. ^bSignificance at P < 0.05. ^aComparison of CPF+GSH.

It has been known to generate oxidative stress by inhibiting enzymatic antioxidant defense (Verma and Srivastava, 2003). Jett and Navoa, (2000) reported an increase in H₂O₂ independent NADPH consuming activity in brain of pups of CPF exposed dams. CPF exposure to rats causes oxidative stress in all parts of brain (Verma et al., 2009). Our result strengthens the hypothesis and suggests that induction of oxidative stress is perhaps the central mechanism by which OP pesticides exert their cellular action. Oxidative damage primarily occurs through production of reactive oxygen species, including hydroxyl radicals and hydrogen peroxide that subsequently react with biological molecules as well as causing damage to membranes and other tissues (Banerjee et al., 1999). A significant decrease in the GSH level and a concomitant increase in LPO level following administration of the pesticide dose were observed in the present study. The decrease in GSH level leads to a net suppression in the total antioxidant capacity since it plays a key role as a substrate for the enzyme glutathione S-transferase (GST) and as a cofactor for a variety of enzymes including glutathione peroxidase (GPx). Also, GSH depletion has been shown to intensify LPO and predispose cells to further oxidant damage (Maellaro et al., 1990).

In the present study, there is a decrease in the serum testosterone level and reduction in spermatogenesis in CPF exposed groups. These results are in consistent with the published data reported that chlorpyrifos at 17.5 mg/kg-d caused adverse reproductive effects in male mice included severe testicular damage and resulted in reduction in sperm count and thus affect the fertility (Joshi et al., 2007). On the other hand, the reduction in spermatogenesis which observed in the exposed groups may simply represent the effects of CPF exposure on sperm parameters, and testis histological changes. Spermatogenesis and fertility are critically dependent upon the maintenance of adequate levels of testosterone (Kidd and James, 1991). Therefore, the effects of CPF on the spermatogenesis in this study can be attributed to its ability to reduce serum testosterone levels and activity of some testicular enzymes. Concerning of the reproductive toxicities of OP pesticide, the methyl parathion caused increasing in the levels of abnormal sperm and testosterone, whereas the luteinizing hormone level and total number of seminiferous tubules decreased in the testis besides a few tubules showed exfoliation of epithelium and vacuoles in the testis of the treated newborn Wistar rat (Narayana et al., 2006). The pesticide vinclozolin, which is known as an endocrine disrupting chemical regarding spermatogenesis and gene expression revealed significant increase in the expression level of mRNAs of the testicular steroidogenic enzyme genes; cytochrome P450 (CYP) side chain cleavage (P450scc or CYP11A) and CYP17A (Kubota et al. 2003).

In the present study, the histochemical expression of the alkaline phosphatase enzyme in the testes of albino rats is decreased due to the toxic effect of CPF exposure. Almost similar observations has also been reported by Seven et al, (2004) that the activity of alkaline phosphatase in the liver of rats due to adverse toxic effects of CPF exposure; while Linn, (1998) due to inhibition of testicular steroideogenesis by the induction of cytochrome P-450, which is the result from decrease steroid hydroxylases and decline lysosomal enzyme alkaline phosphatase or the activation of CPF by microsomal monooxygenase in the testes, in the presence of NADPH and oxygen which might result from decline the enzymes in the target tissue (Kubota et al. 2003). The mechanism of action of some OP on the testes involves induction of cytochrome P-450 and significant increase in the expression level of mRNAs of the testicular steroidogenic enzyme genes; cytochrome P450 (CYP) side chain cleavage (P450scc or CYP11A) and CYP17A resulting in decreases in the activities of steroid hydroxylases and enzymes. The metabolites of CPF is appeared to be an important in the biological activity of the pesticide and is responsible for the toxic side effects of the pesticide on the testicular cytochrome P-450 and enzymes level (Mutch and Williams, 2007).

The testicular histomorphological studies of CPF exposed group revealed that a significant decrease in spermatogenic cells of the seminiferous tubules which dissociated from each other and also necrosis in some seminiferous tubules accompanied with edema in the interstitial tissue. In addition, there was a significant decrease in the mean number of different germ cell types in all stages of the seminiferous tubules. Moreover, the mean number and nuclear volume of Leydig cells were significantly decreased as compared with control. These findings were in consistent with Debnath and Mandal, (2000) they detected that the OP insecticide pollutant quinalphos induced shrinkage of the tubular diameter and testicular atrophy leading to degenerative changes in the germinal epithelium in albino rats. The reproductive toxicity of CPF in male mice was studied by Farag et al, (2010). They reported that CPF caused testicular lesions characterized by markedly decreased testes weight with moderate to severe widening of interstitial spaces and partial arrest of spermatogenesis at the high level dose of CPF at 25 mg/kg-d. The obtained decrease in the testicular spermatogonia and spermatid indicated that spermatogenesis was partially arrested at the CPF exposed group. These results are in consistent with the published data reported that CPF at 17.5 mg/kg-d caused adverse reproductive effects in male mice included severe testicular damage and resulted in reduction in sperm count and thus affect the fertility (Joshi et al.,2007).

Indeed, decreased in Sertoli, Leydig and germ cell numbers of male rat observed in this study are all related indicators for hypothyroidism and lowered testosterone level at 17.5 mg/kg-d. CPF was reported to be a potential endocrine disrupter by depression of sperm T4 level in (Rawlings et al., 1998). Recent study has suggested that one critical molecular target of thyroid hormone in the Leydig cell is the steroidogenic acute regulatory (StAR) protein, which is responsible for cholesterol transport across the outer mitochondrial membrane for testosterone production (Walsh et al., 2000 and Manna et al., 2001 a, b).

Glutathione, the major water -soluble antioxidant, is known to protect cellular membranes and lipoproteins from peroxidation (Rana et al., 2002), may minimize lipid peroxidation in biological systems (Selvam, 2002) and acts to protect both cytosol membranes against free radical attack (Hogg et al., 1998). Its high electron donating capacity combined with its high intracellular concentration endows GSH with great reducing power, which is used to regulate a complex thiol exchange system.

5. Conclusion

Our results suggest that exposure to CPF induces depletion in antioxidant defense systems in the testes indicating CPF-induced oxidative stress in the testis. This effect may lead to disruption in the functional integrity of cell organelles. The present study also suggests that co-administration of GSH with CPF prevents the adverse effects of CPF on antioxidant status as well as improving testosterone hormone level, spermatogenesis, testicular histopathological alterations in adult rats. In conclusion the adverse effect of CPF on male reproduction of rats may be due to the induction of oxidative stress. These effects could be alleviated by non-enzymatic water soluble antioxidant glutathione.

References

- Aitken, J.R., Clarkson, J.S., 1987. Cellular basis of defective sperm function and its association with the genesis of reactive oxygen species by human spermatozoa. *J Reprod Fertil.* 81, 459–69.
- Aitken, J.R., Clarkson, J.S., Fishel, S., 1989. Generation of reactive oxygen species, lipid peroxidation and humal sperm function. *Biol. Reprod.* 40, 183–97.
- Bagchi D, Balmoori J, Bagchi M, Ye X, Williams CB, Stohs SJ. 2002. Comparative effects of TCDD, endrin, naphthalene and chromium (IV) on oxidative stress and tissue damage in the liver and brain tissues of mice. *Toxicol.* 175,73–82.
- Bairy, K.L., (2006). Neonatal methyl parathion exposure affects the growth and functions of the male reproductive system in the adult rat. *Folia. Morphol. (Warsz)* 65, 26–33
- Banerjee, B.D., Seth, V., Bhattacharya, A., Pasha, S.T., Chakraborty, A.K., 1999. Biochemical effect of some pesticides on lipid peroxidation and free radical scavengers, *Toxicol. Lett.* 107, 33–37.
- Buege, J.A., Aust S.D., 1978. Microsomal lipid peroxidation, *Methods Enzymol.* 52, 302–310.
- Carlberg, I., Mannervik, B., 1975. Purification and characterization of the flavoenzyme glutathione reductase from rat liver. *J. Biol. Chem.* 250, 5474–5480.
- Chitra, K.C., Sujatha, R., Latchoumycandane, C., Mathur, P.P., 2001. Effect of lindane on antioxidant enzymes in epididymis and epididymal sperm of adult rats. *Asian. J. Androl.*; 3, 205–8.
- Debnath, D., Mandal, T.K., 2000. Study of quinalphos (an environmental oestrogenic insecticide) formulation (Ekalux 25 E.C.)-induced damage of the testicular tissues and antioxidant defence systems in Sprague–Dawley albino rats. *J. Appl. Toxicol.* 20,197–204.
- Farag, A.T., El-Okazy, A.M., El-Aswed, A.F., 2003. Developmental toxicity study of chlorpyrifos in rats. *Reprod. Toxicol.* 17, 203–8.
- Farag, A.T., Radwana, H.A., Sorourb,F., El Okazyc, A., El-Agamyd, E., El-Sebaea, A., (2010). Chlorpyrifos induced reproductive toxicity in male mice. *Reprod. Toxicol.* 29, 80–85.
- Franca, L.R., Hass, R.A., Cooke, P.S. and Russell, L.D., 1995. Neonatal hypothyroidism causes delayed Sertoli cell maturation in rats treated with propylthiouracyl: evidence that the Sertoli cell controls testis growth. *Anat. Rec.* 242, 57 – 69.

- Gultekin, F., Delibas, N., Yasar, S., Kilinc, I., 2001. In vivo changes in antioxidant systems and protective role of melatonin and a combination of vitamin C and vitamin E on oxidative damage in erythrocytes induced by chlorpyrifos-ethyl in rats. *Arch. Toxicol.* 75, 88–96
- Gurunathan, S.J., Bukowske, P.J., 1998. Accumulation of chlorpyrifos on residential surfaces and toys accessible to children. *Environ. Health Perspect.* 106.
- Hogg, N., Sem, 1998. *Reprod. Endocrinol.* 16,241.
- Jett, D.A., Navoa, R.V. 2000. In vitro and in vivo effects of chlorpyrifos on glutathione peroxidase and catalase in developing rat brain. *Neuro Toxicology.* 21, 141–146.
- Joshi, S.C., Mathur, R., Gulati, N., 2007. Testicular toxicity of chlorpyrifos (an organophosphate pesticide) in albino rat. *Toxicol. Ind. Health.* 23 (7), 439–44.
- Karanth, S., Liu, J., Oliver, K., Pope, C., 2004. Interactive toxicity of the organophosphorus insecticides chlorpyrifos and methyl parathion in rats, *Toxicol. Appl. Pharmacol.* 196, 183–190.
- Kidd, H., James, D.R., 1991. *The agrochemicals handbook.* 3rd ed. Cambridge, UK: Royal Society of Chemistry Information Services.
- Kobayashi, T., Miyazaki, T., Natori, M., Nozawa, S., 1991. Protective role of superoxide dismutase in human sperm motility: superoxide dismutase activity and lipid peroxide in human seminal plasma and spermatozoa. *Hum. Reprod.* 6, 987–91.
- Kubota, K., Ohsako, S., Kurosawa, S., Takeda, K., Qing, W., Sakaue, M., Kawakami, T., Ishimura, R., Tohyama, C., 2003. Effects of vinclozolin administration on sperm production and testosterone biosynthetic pathway in adult male rat. *J. Reprod. Dev.* 49, 403–412.
- Latchoumycandane, C., Chitra, K.C., Mathur, P.P., 2002. The effects of 2,3,7,8- tetrachlorodibenzo-p-dioxin on the mitochondrial and microsomal fractions of rat testis. *Toxicol.* 171, 127–35.
- Layne, E.L., Coddington, A.B., Ramjit, H.G. and Calby, H.O. 1993. Identification of spironolactone metabolites in plasma and target organs of guinea pig. *Drug. Metabol. Dispos.*, 21 (6), 1086- 90.
- Lee, A., East, J., Balgaug, P., 1991. Interactions of insecticides with biological membranes. *Pestic. Sci.* 32, 317–327.
- Linn, S., 1998. DNA damage by iron and hydrogen peroxide in vitro and in vivo. *Drug Metab. Rev.* 30, 313–326.
- Lodovici M, Aioli S, Monsenat C, Dolara P, Medica A, Di Simplicio P. 1994. Effect of mixture of 15 commonly used pesticides on DNA levels of 8-hydroxy-2-deoxyguanosine and xenobiotic metabolizing enzymes in rat liver. *J. Environ. Pathol. Toxicol. Oncol.* 13,163–168.
- Maellaro, E., Casini, A.F., Dell Bello, B., Comporti, M., 1990 . Lipid peroxidation and antioxidant systems in the liver injury produced by glutathione depleting agents, *Biochem. Pharmacol.* 39, 1513–1521.
- Manna. P.R., Roy, P, Clark, B.J., Stocco, D.M., Huhtaniemi, I.T., 2001a. Interaction of thyroid hormone and steroidogenic acute regulatory (StAR) protein in the regulation of murine leydig cell steroidogenesis. *J. Steroid Biochem. Mol. Biol.* 76, 167–77.
- Manna, P.R., Kero, J., Tena-sempere, M., Pakarinen, P., Stocco, D.M., Huhtaniemi I.T. 2001b. Assessment of mechanisms of thyroid hormone action in mouse leydig cells: regulation of the steroidogenic acute regulatory protein, steroidogenesis, and luteinizing hormone receptors function. *Endocrinol.* 142, 319–31.
- Marklund, S., Marklund, G., 1974. Involvement of superoxide anion radical in autooxidation of pyrogallol and a convenient assay for superoxide dismutase. *Eur. J. Biochem.* 47, 469–474.
- Marrs, T.C., 1993. Organophosphate poisoning, *Pharmacol. Ther.* 58, 51–66.
- Murono, E.P., Lin, T., Osterman, J., Nankin, H.R., 1980. The effects of cytochalasin B on testosterone synthesis by interstitial cells of rat testis. *Biochem. Biophys. Acta.*, 633:228–36.
- Mutch, E., Williams, F.M., 2007. Diazinon, Chlorpyrifos and parathion are metabolised by multiple cytochrome P450 in human liver, *Toxicol.* 224, 22–32.
- Narayana, K., Prashanthi, N., Nayanatara, A., Kumar, H.H., Abhilash, K., Bairy, K.L, 2006. Neonatal methyl parathion exposure affects the growth and functions of the male reproductive system in the adult rat. *Folia. Morphol. (Warsz)* 65, 26–33.
- Peltola, V., Mantalya, E., Huhtaniemi, I., Ahotupa, M., 1994. Lipid peroxidation and antioxidant enzyme activities in the rat testis after cigarette smoke inhalation or administration of polychlorinated biphenyls or polychlorinated naphthalenes. *J. Androl.* 15, 353–61.
- Qiao, D., Seidler, F.J., Tate, C.A., Cousins, M.M., Slotkin, T.A., 2003. Fetal chlorpyrifos exposure: adverse effects on brain cell development and cholinergic biomarkers emerge postnatal and continue into adolescence and adulthood. *Environ. Health Perspect.* 111, 536–44.

- Rana, S.V.S., Allen, T., Singh, R., 2002. Inevitable glutathione, then and now. *Indian J. Exp. Biol.* 40,706–16.
- Rawlings, N.C., Cook, S.J., Waldbillig, D., 1998. Effects of the pesticides carbofuran, chlorpyrifos, dimethoate, lindane, triallate, trifluralin, 2,4-D, and pentachlorophenol on the metabolic endocrine and reproductive endocrine system in ewes. *J. Toxicol. Environ. Health. A*; 54(1),21–36.
- Richardson, R.J., Moore, T.B., Kayyali, U.S., Fowke, J.H., Randall, J.C., 1993. Inhibition of hen brain acetylcholinesterase and neurotoxic esterase by chlorpyrifos in vivo and kinetics of inhibition by chlorpyrifos oxon in vitro: application to assessment of neuropathic risk, *Fundam. Appl. Toxicol.* 20, 273–279.
- Selvam, R., 2002. Calcium oxalate stone disease: role of lipid peroxidation and antioxidants. *Urol. Res.* 30, 35–47.
- Setchell, B.P., (1974). Secretions of the testis and epididymis. *J. Rep. Fert.* 37, 165-177.
- Seven, A., Guzel, S., Seymen, O., Civelek, S., Bolayirli, M., Uncu, M., Burcu, G., 2004. Effects of vitamin E supplementation on oxidative stress in streptozotocin induced diabetic rats: investigation of liver and plasma. *Yonsei Med. J.* 45, 703–710.
- Sujatha, R., Chitra, K.C., Latchoumycandane, C., Mathur, P.P., 2001. Effect of lindane on testicular antioxidant system and steroidogenic enzymes in adult rats. *Asian J. Androl.* 3, 135–8.
- Suresh Babu, N., Malik, J.K., Rao, G.S., Aggarwal, M., Ranganathan, V., 2006. Effects of subchronic malathion exposure on the pharmacokinetic disposition of pefloxacin. *Environ. Toxicol. Pharmacol.* 22, 167–171.
- Tian, Y., Ishikawa, H., Yamaguchi, T., Yamauchi, T., Yokoyama, K., 2005. Teratogenic and developmental toxicity of chlorpyrifos maternal exposure during organogenesis in mice. *Reprod. Toxicol.* 20, 267–71.
- USDA, 1994. *Agriculture Chemical Usage. Field Crop Study.* Washington,DC, U.S. Department of Agriculture, pp. 396–432.
- Verma, R.S., Srivastava, N., 2001. Chlorpyrifos induced alterations in levels of thiobarbituric acid reactive substances and glutathione in rat brain. *Indian J. Exp. Biol.* 39, 174–177.
- Verma, R.S., Srivastava, N., 2003. Effect of chlorpyrifos on thiobarbituric acid reactive substances, scavenging enzymes and glutathione in rat tissues. *Indian J. Biochem. Biophys.* 40, 423–428.
- Verma, R.S., Mehta, A., Srivastava, N., 2007. In vivo chlorpyrifos induced oxidative stress: attenuation by antioxidant vitamins. *Pestic. Biochem. Phys.* 88, 191–196.
- Verma, R.S.A., Mehta, A., Srivastava, N., (2009). Comparative studies on chlorpyrifos and methyl parathion induced oxidative stress in different parts of rat brain: Attenuation by antioxidant vitamins. *Pesticide Biochem. Physiol.* 95, 152–158.
- Walsh, L.P., McCormick, C., Martin, C., Stocco, D.M., 2000. Roundup inhibits steroidogenesis by disrupting steroidogenic acute regulatory (StAR) protein expression. *Environ. Health Perspect.* 108, 776–96.
- WHO, The WHO 1997. *Recommended Classification of Pesticides by Hazard 1996–1997, International Programme on Chemical Safety, WHO/IPCS/96.3.*
- Yasmashita, M., Tanaka, J., Ando, Y., 1997. Human mortality in organophosphate poisonings, *Vet. Hum. Toxicol.* 39, 84–85.