

Contents lists available at Sjournals

Scientific Journal of
Biological Sciences

Journal homepage: www.Sjournals.com



Original article

An histochemical study of the effects of immunosuppressive drug azathioprine on the cytoarchitecture of the testes of adult wistar rats (*rattus norvegicus*)

I.O. Onanuga*, R.B. Ibrahim, R. Jaji-Sulaimon, C.N.B. Tagoe, O.B. Akinola

Department of Anatomy, Faculty of Basic Medical Sciences, College of Health Sciences, University of Ilorin; P.M.B. 1515, Ilorin, Nigeria.

*Corresponding author; Department of Anatomy, Faculty of Basic Medical Sciences, College of Health Sciences, University of Ilorin; P.M.B. 1515, Ilorin, Nigeria.

ARTICLE INFO

ABSTRACT

Article history:

Received 21 December 2013

Accepted 23 January 2014

Available online 29 January 2014

Keywords:

Azathioprine

Ascorbic acid

Testis

Reticulin

Collagen

In this study we employed some histochemical techniques to evaluate the effect of ascorbic acid on azathioprine-induced alterations in the testis of adult Wistar rats. Male adult Wistar rats (n=30) with mean weight 210 ± 2.65 g were assigned into four treatment (n=24) and control (n=6) groups. Animals were treated with 25 and 50 mg/kg azathioprine (AZA) alone (Grps II and IV) and in combination with 25 and 50 mg/kg ascorbic acid (Grps III and V) for 21 days while control animals received 1 ml distilled water. 24 h Post-treatment, animals were sacrificed, their testes were excised, weighed and fixed in Bouin's fluid for histochemical studies of reticulin and collagen. The histochemical findings of testis sections indicated cyto-architectural distortions in the treated groups when compared to the control group. This findings show that ascorbic acid at doses administered did not ameliorate the damages caused by azathioprine.

© 2014 Sjournals. All rights reserved.

1. Introduction

The importance of the immune system in the body's protection against harmful foreign molecules is well recognized. However, in some instances, this protection can result in serious problems. The introduction of an allograft can elicit damaging immune response; causing rejection of transplanted tissue. Tissue and organ transplant are now routinely done due to improved surgical techniques, better tissue typing and development of drugs that more selectively inhibit rejection of transplanted tissue while preventing the patient from becoming immunologically compromised (Richard et al., 2008)

Azathioprine is an immunomodulatory drug often used to treat inflammatory bowel disease, prevent rejection of transplanted organs and also used as anticancer drug. However, its use does not necessarily come without a price. By suppressing the immune system, and lowering the number of infection-fighting white blood cells, Azathioprine makes an individual more susceptible to infection. Following oral ingestion of azathioprine, it is metabolized into the active 6-mercaptopurine (6-MP) which itself is a purine synthesis inhibitor (Barbara, 2010). 6-Mercaptopurine impedes DNA synthesis and thus inhibits the proliferation of cells, especially the fast-growing lymphocytes. T-cells and B-cells are particularly affected by this inhibition of purine synthesis (Maltzman and Koretzky, 2003). Azathioprine blocks the downstream effects of CD28 co stimulation. 6-MP interacts directly with GTP-binding protein Rac1, thus blocking up-regulation of BCL-x1 mRNA and protein. In vivo data indicates that inflammatory bowel disease patients treated with azathioprine have more apoptotic mononuclear cells than untreated controls; this indicates that this mechanism may be responsible for the in vivo response to the drug in this disease (Maltzman and Koretzky, 2003). Immediate or short-term side-effects are uncommon, but these may include nausea, fatigue, hair loss, and rash. Due to azathioprine's immunosuppressive action it makes patients will be more susceptible to infection and acute pancreatitis especially in patients with Crohn's disease (Weersma et al., 2004). Previous reports have shown that Azathioprine (AZP) affect spermatogenesis in rat with significant reduction of serum level of testosterone (Iwasaki et al., 1996). Ascorbic acid or L-ascorbic acid is an essential nutrient for humans where it functions as vitamin. Ascorbate (an ion of ascorbic acid) is required for a range of essential metabolic reactions in all animals and plants (Higdon and Vitamin, 2003). It is a water soluble anti-oxidant which protects the body from oxidative stress, and also serves as a co-factor in several vital enzymatic reactions (Padayathy et al., 2003). Thus, in this study, we investigated using histochemistry the morphologic and oxidative changes in the testis of Wistar rats exposed to immunosuppressive drug-azathioprine and the possible protective effects of ascorbic acid.

2. Materials and methods

2.1. Drugs

A commercial available formulation of azathioprine (AZA) tablets 50 mg and ascorbic acid (Vitamin C) syrup were bought from Tuyil Pharmaceutical Industry, Ilorin, Kwara State. Each ml of ascorbic acid contains 20 mg of ascorbic acid.

2.2. Experimental animals

Adult male Wistar rats were procured from department of Biochemistry, University of Ilorin, Nigeria. They were housed within the Animal House of the Department of Anatomy, College of Health Sciences, University of Ilorin, in different cages at room temperature, and maintained under a 12 h light/ 12 h dark cycle, with feeds and water available ad libitum. They were allowed to acclimatize for two weeks before the commencement of the experiment.

2.3. Experimental design

A total of thirty (30) adult male Wistar rats of mean weight of 210 ± 2.65 g were used for the experiment. Post-acclimatization, animals were assigned to five groups (n=6) as follows:

Group I animals received distilled water (1 ml, p.o.).

Group II received AZA (10 mg/kg, p.o.).

Group III received AZA (10 mg/kg, p.o.) simultaneously with ascorbic acid (25 mg/kg, p.o.).

Group IV received AZA (20 mg/kg, p.o.).

Group V received AZA (20 mg/kg, p.o.) simultaneously with ascorbic acid (50 mg/kg, p.o.). All treatment lasted for 21 days.

2.4. Body weight

Body weights of the rats were taken prior to the administration of azathioprine and ascorbic acid and weekly thereafter.

2.5. animal sacrifice and sample collection

Twenty four hours post treatment; the animals were sacrificed by cervical dislocation. A midline abdominal incision was made to open up the abdominal cavity and access the reproductive organs. The testes were excised and weighed using an electronic sensitive analytical balance (Gallenkomp FA2104A, England). The right testes was then fixed quickly in Bouin's fluid and processed for light microscopic examination using Gordon and Sweets' 8 silver impregnation and Masson's trichrome techniques 9 for histochemical demonstration of reticulin and collagen fibres respectively.

2.6. Tissue processing for light microscopy

After fixation, paraffin embedding was done, sections were obtained at 4 µm using the Reichert-Jung 2050 rotary microtome, followed by Gordon and sweets' 8 and Masson's trichrome 9 staining for reticulin and collagen respectively. Photomicrographs were taken with a digital camera.

2.7. Statistical analysis

Data were analysed using SPSS 16.0 (SPSS Inc, Chicago, USA) at $p < 0.05$ and Excel 2007 (Microsoft Corporation, USA). Data were expressed as mean \pm SEM. Means were compared using the students' T-test.

3. Results

3.1. Body and testicular weight changes

There was marked morphological changes in the testes of all animals in the treatment groups when compared to control (group I). There was also relative increase in weight, weekly recorded for both the control and treated animals. This weight gain was however highest in the control group I and was statistically significant ($p < 0.05$) as shown in Table 1.

Table 1

Weights of Animals.

Group	n	Final body weight (g)	Initial body weight (g)	Weight diff (g)	Testicular weight (g)
A	6	330 \pm 10.83*	221 \pm 1.39*	+109	1.35 \pm 0.0
B	6	219 \pm 1.49	184 \pm 1.49	+35	0.96 \pm 0.1
C	6	237 \pm 2.47*	177 \pm 2.47*	+60	0.75 \pm 0.1
D	6	242 \pm 6.65	212 \pm 6.51	+30	1.16 \pm 0.6
E	6	226 \pm 1.38	195 \pm 1.38	+29	1.17 \pm 0.1

* $p < 0.05$ (statistically significant difference compared with control group).

Comparing the testis-body weight ratio, using t-test at ($P < 0.05$), there was no significant difference between the control group I and the experimental groups II, III, IV and V (table 1).

3.2. Histochemical observations

The testis of the control group I show well preserved reticular connective tissue or reticulin fibres (Fig. 1A). It shows normal section of spermatogenic epithelium and basement membrane (Fig. 1A) compared with the testes of the treated groups II, III, IV and V rats that show less preserved reticular connective tissue or reticulin fibres with thin spermatogenic epithelium and wide lumen (Figs. 1B-E).

As revealed in (Fig.2A), intact collagen fibres with a well preserved section of spermatogenic epithelium and basement membrane were seen in the control group. In comparison with treated groups II, III, IV and V rats their testes show less preserved collagen fibres with thin spermatogenic epithelium and wide lumen (Figs. 2B-E).

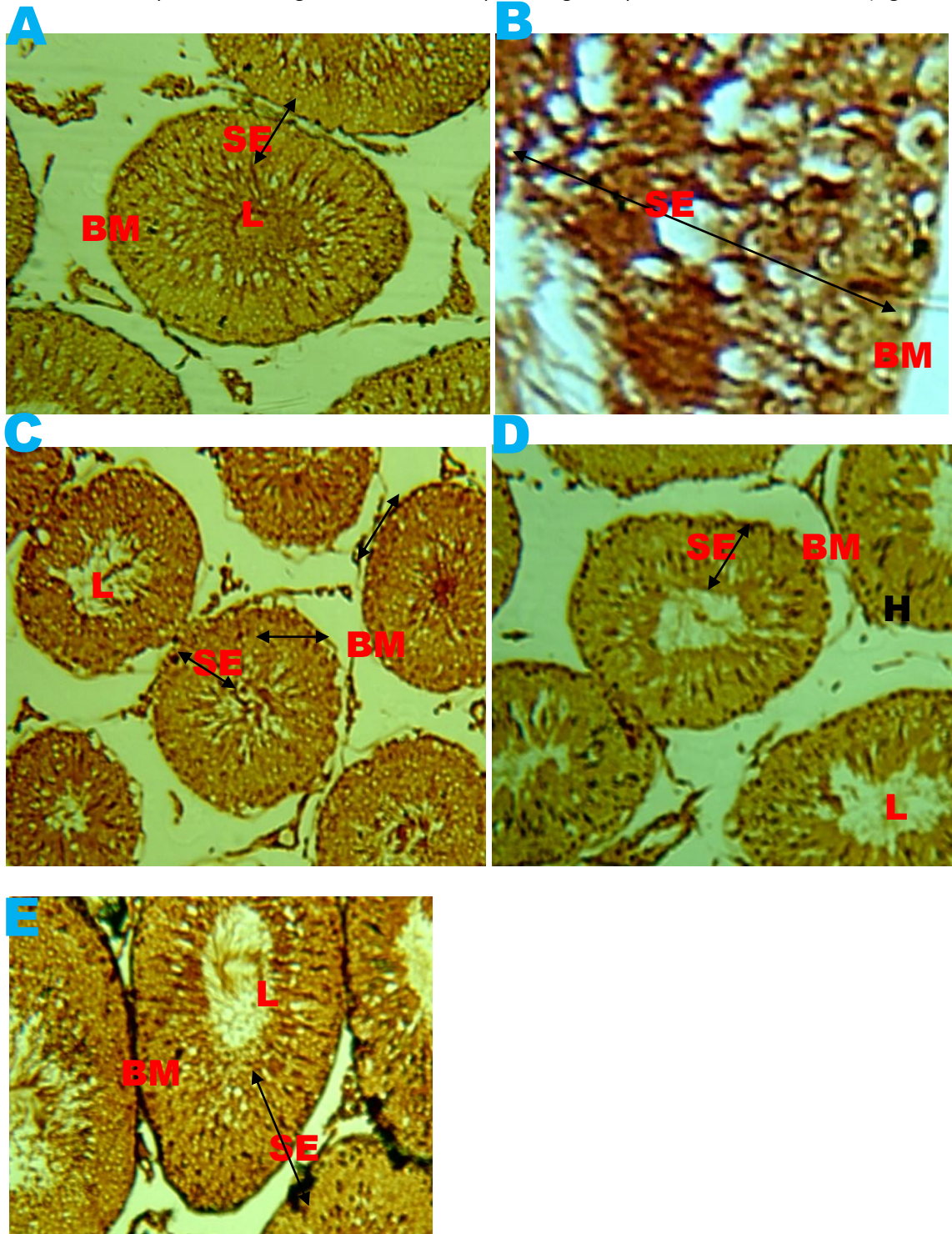


Fig. 1(A-E). Photomicrograph of the testis of a control animal (A) showing normal SE-seminiferous epithelium, BM-basement membrane, L-Lumen, more positive for reticulin fibres compares with sections of treated rats (B-E). (G&S $\times 100$).

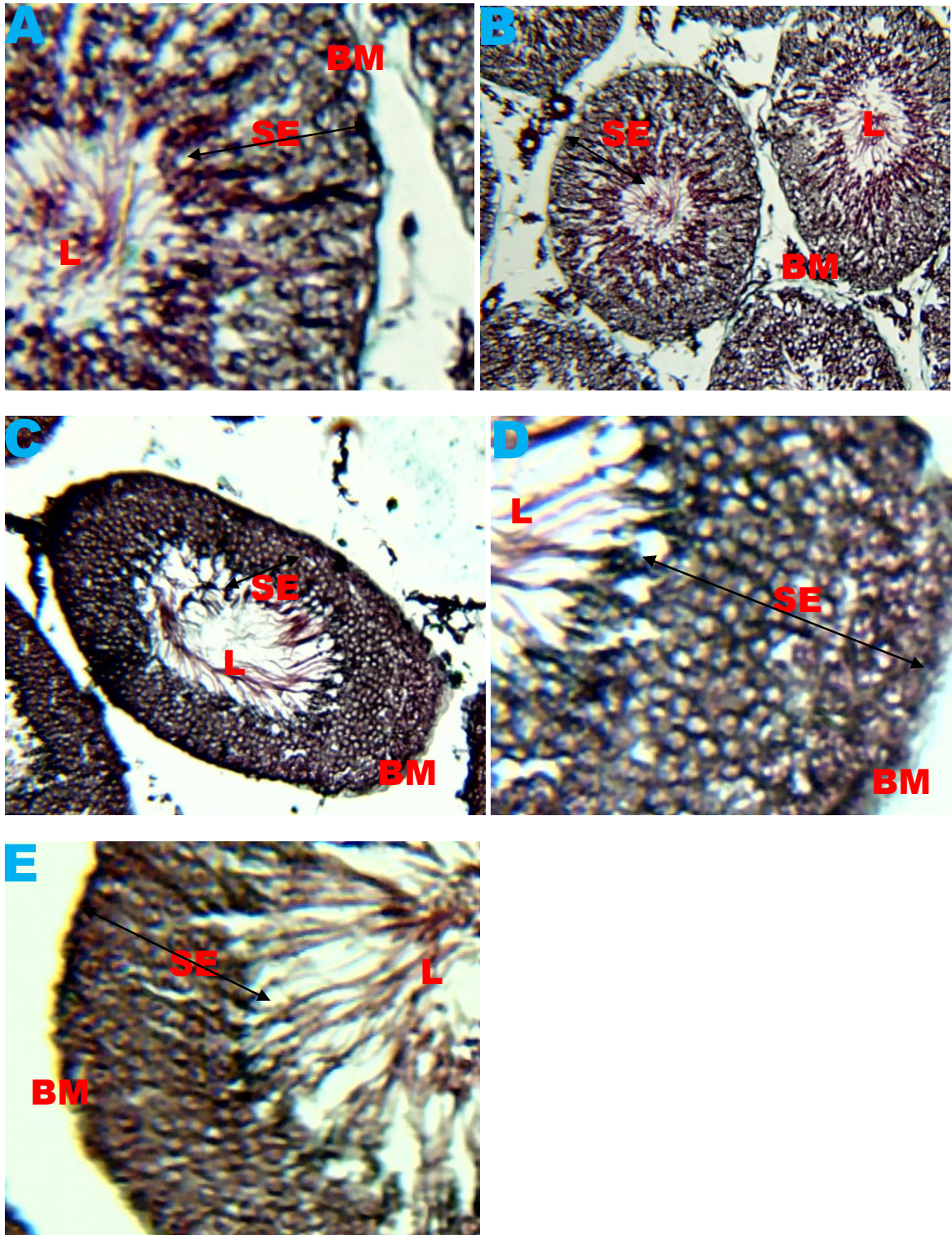


Fig. 2(A-E). Photomicrograph of the testis of the control animal (A) showing normal SE-seminiferous epithelium, BM-basement membrane, L-Lumen, more positive for collagen fiber compared with treated rats (B-E). (Masson's trichrome $\times 100$).

4. Discussion

The findings of the present study show that azathioprine is deleterious to the testis and administration ascorbic acid administered at these doses did not ameliorate the damages resulting from azathioprine administration.

Previous study has shown that consumption of AZA has some beneficial and therapeutic effects on the body. AZA has been used in the management and prevention of rejection following organ transplantation.

Azathioprine is also used to treat a vast array of autoimmune diseases, such as inflammatory bowel diseases, multiple sclerosis, atopic dermatitis, autoimmune hepatitis, myasthenia gravis and restrictive lung disease, rheumatoid arthritis and pemphigus (Maltzman and Koretzky, 2003).

It has been reported that azathioprine, cyclosporine, and methotrexate injured spermatogenesis in rat with serum level of testosterone significantly lower immediately after the oral administration of AZA.5

The current study shows that consumption of AZA at doses of 10 mg/kg and 20 mg/kg lead to impairment in the quantity and quality of connective tissues in the testes of adult Wistar rats. The weight gain being highest in the control group is consistent with expected findings considering possible toxic effects of the treatment agent.

The reticulin fibres reaction is well demonstrated in the spermatogenic epithelium and basement membrane by Gordon and Sweet silver impregnation. The intensity of the black stain was greater in the control compared to the treatment groups. The black stain was more in the 10 mg/kg body weight of AZA and 25 mg/kg body weight of ascorbic acid groups compared to the 20 mg/kg body weight of AZA and ascorbic acid 50 mg/kg body weight of ascorbic acid groups. The higher intensity of the stain, positivity of the argilophilic-black, means the presence of more reticulin fibres, which consists of fine branching fibres which give a supporting framework to the richly cellular tissue of the testis. Reticular fibres enhance spermatogenesis and are basis for the good outcome of the testicular morphology. This observation is in agreement with the work of Iwasaki5 who reported that the seminiferous tubules were affected in a dose dependent manner following azathioprine administration. Similarly report indicates seminiferous tubules distortion and atrophy following azathioprine administration (Karawya and El-Nahas, 2005).

The collagen fibres reaction is well demonstrated in the connective framework by Masson's trichrome technique. The intensity of the blue stain is greater in the control compared to the treatment groups. The blue stain is more in the 10 mg/kg body weight of AZA group compared to the 20 mg/kg body weight of AZA. The greater the intensity of the stain and positivity of the blue colour is an indication of more collagen fibres which consists of fine branching fibres which give a supporting framework to the richly cellular tissue of the testis. Collagen fibres enhance spermatogenesis.

In the azathioprine-treated animals, there was widening of the interstitial spaces. This was mainly observed in rats that received 20 mg/kg body weight of azathioprine. This observation is in agreement with that of Karawya and El-Nahas (2005) who reported widening of the interstitial spaces due to edema in azathioprine-treated rats. The spermatogenic series cells were also reduced in size and number. This could lead to low sperm counts as reported by Ramirez et al., (1991).

5. Conclusion

The current study revealed that the consumption of the azathioprine, particularly when consumed at 20 mg/kg body weight, has deleterious effect on the quality and the quantity of the connective tissues characteristics of the adult male Wistar rats that is reticular and collagen fibres, hence on the integrity of the rat testis. These damages were not ameliorated with the administration of ascorbic acid.

References

- Avwioro, O.G., 2002. *Histochemistry and Tissue Pathology: Principle and Techniques*. 1st Ed. Clavarianum Centre., pp. 175-180.
- Bancroft, J.D., Steven, S.A., 1990. *Theory and Pract. Histolog. Techn.*, 2nd ed. pp. 133-134.
- Barbara, S., 2010. *Inflammatory Bowel Disease and Male Fertility*. The Arthur Smith Institute for Urology of the North Shore-LIJ Health System. Long Island., NY, 516, 734-850.
- Higdon, J., Vitamin, C., 2003. Oregon State University, Micronutrient information Center. Ret., 2007-03-07.
- Iwasaki, M., Fuse, H., Katayama, T., 1996. The effects of cyclosporin azathioprine and mizoribine on male reproduction in rats. *Nihon Hinyokika Gakkai Zasshi.*, 87(1), 42-49.

- Karawya, S.F., El-Nahas, A.F., 2005. The protective effect of vitamin C on azathioprine-induced seminiferous tubular structural changes and cytogenetic toxicity in albino rats. *Cancer Ther.*, 4, 125-134.
- Maltzman, J.S., Koretzky, G.A., 2003. Azathioprine: Old drug, new actions. *J. Clin. Invest.*, 111(8), 1122–1124.
- Padayathy, S., Katz, A., Wang, Y., 2003. Vitamin C as an antioxidant: evaluation of its role in disease prevention. *J. Am. Coll. Nutr.*, 22(1), 18-25.
- Ramirez, G., Narvarte, J., Bittle, P.A., 1991. Cyclosporine-induced alterations in the hypothalamic hypophyseal gonadal axis in transplant patients. *Nephron.*, 58, 27-32.
- Richard, A.H., Richard, D.H., Mary, J.M., Pamela, C.C., 2008. Lippincott's Illustrated. *Rev. Pharmacol.*, 3rd Ed. LIPPICOTT WILLIAMS & WILKINS, pp. 485.
- Weersma, R.K., Peters, F.T.M., Oostenbrug, L.E., 2004. Increased incidence of azathioprine-induced pancreatitis in Crohn's disease compared with other diseases. *Aliment. Pharmacol. Therapeut.*, 20(8), 843–850.