



Original article

Adoption of improved millet varieties by farmers in Argungu local government area of Kebbi State

D.A. Adekomi^{a,b,*}, A.M. Afodun^c, K.K. Quadri^d, T.D. Adeniyi^e

^aDepartment of Anatomy and Cell Biology, Obafemi Awolowo University, Ile-Ife, Osun State, Nigeria.

^bDepartment of Anatomy, College of Medicine and Health sciences, Afe Babalola University, Ado, Ekiti State, Nigeria.

^cDepartment of Anatomy, Faculty of Basic Medical Sciences, University of Ilorin, Ilorin, Nigeria.

^dDepartment of Physiology, University of Lagos, Lagos, Nigeria.

^eDepartment of Anatomy, College of Medicine, Osun State University, Osogbo, Osun State, Nigeria.

*Corresponding author; Department of Anatomy and Cell Biology, Obafemi Awolowo University, Ile-Ife, Osun State, Nigeria.

ARTICLE INFO

ABSTRACT

Article history:

Received 03 December 2013

Accepted 18 December 2013

Available online 28 December 2013

Keywords:

Kidney

Liver

Normal saline

Histopathology

prague-Dawley Rats

The aim of this investigation was to evaluate some of the effects of aqueous leaf extract of *Salvia officinalis* on the kidney and liver of male Sprague Dawley rats. Ten Sprague-Dawley rats (7-11 weeks old) were randomly assigned into two groups; A and B. Aqueous extract of *S. officinalis* leaves (300 mg/kg body weight) was administered orally to the rats in group B while the rats in group A received equal volume of normal saline for 14d. At termination of treatment, the histopathology of the kidney and liver were assessed. The kidney and the liver in the extract treated rat displayed organized and preserved histological profile. Our findings suggest that *S. officinalis* has no deleterious effects on the kidney and liver of the rats.

© 2013 Sjournals. All rights reserved.

1. Introduction

Indeed the use of plants (including fruits and seeds) in their natural unprocessed and unrefined form undoubtedly began when the first "intelligent animal" observed that certain plants altered particular body function

(Katzung, 2004). Medicinal plants are plants that have at least one of their biochemical components and/or structural parts (flowers, leaves, stem, seeds, barks or roots) used for therapeutic purposes (Bruneton, 1993). Recently, medicinal plants have become of immense use in the treatment of different disease conditions, such as diabetes, malaria, and anemia (Fola, 1993) to mention but few. The availability and relatively cheaper cost of medicinal plants makes them more useful as therapeutic agents when compared to 'modern' medicines (Agbor and Ngogang, 2005; Agbor et al., 2005). The importance of medicinal plants, and the contribution of phytomedicine to the clinical well-being of a significant number of the world's population, has attracted interest from a variety of disciplines (Prosper-Cabral et al., 2007).

The trado-medicinal potentials of *Salvia officinalis* in clinical trials and folklore medicine are well documented in various researches and investigations (Perry et al., 2000; Perry et al., 2003; Savelev et al., 2004; Bartram, 1995; Kuang and Xiang, 1994; Moretti et al., 1997; Zupko et al., 2001; Clebsch and Carol, 2003).

Salvia officinalis is a small evergreen perennial shrub. It is a member of the family *Lamiaceae* and is native to the Mediterranean region, although it has naturalized itself in many places such as Africa. It has a long history of medicinal and culinary potentials. It has been cultivated for centuries in the Old World for its nutritious values and healing properties (Clebsch and Carol, 2003). Phytochemical analysis of the plant showed that it contains tannic acid, cineole, oleic acid, ursolic acid, ursolic acid, cornsole, cornsolic acid, fumaric acid, chlorogenic acid, caffeic acid, niacin, nicotinamide, flavones, flavonoid glycosides, thujone and estrogenic substances (The Herb Society of America, 2001).

The consumption of a variety of local herbs and vegetables by man is believed to contribute significantly to the improvement of human health, in terms of prevention, and or cure of diseases because plants have long served as a useful and natural source of the therapeutic agents. There is growing focus to follow systematic research methodology and to evaluate scientific basis for the traditional herbal medicines that are claimed to possess medicinal potentials.

The Liver is the largest gland in the mammalian body. It has both macro-and micro- structures. The micro-morphology is highlighted by the lobules and their sinusoids that are lined with active phagocytes known as Kupffer cells, central veins and hepatocytes plates that are closely associated with the terminal lymphatics and bile canaliculi. These morphological features have enabled the liver to carry out a very vast physiological functions such as: production of bile, which helps carry away waste and break down fats in the small intestine during digestion, production of certain proteins for blood plasma, production of cholesterol and special proteins to help carry fats through the body, conversion of excess glucose into glycogen for storage (glycogen can later be converted back to glucose for energy), regulation of blood levels of amino acids, which form the building blocks of proteins, processing of hemoglobin for use of its iron content (the liver stores iron), conversion of poisonous ammonia to urea (urea is an end product of protein metabolism and is excreted in the urine), clearing the blood of drugs and other poisonous substances, regulating blood clotting, resisting infections by producing immune factors and removing bacteria from the bloodstream. The hepatocytes have metabolic functions that deal with very essential processes such as detoxification, deamination, transamination, removal of ammonia in the form of urea, biosynthesis and release of the non-essential amino acids and plasma proteins with the exception of immuno gamma globulins, gluconeogenesis, storage of glycogen, conversion of carbohydrates and proteins into lipids, synthesis of lipoproteins, phospholipids and cholesterol, oxidation of fatty acids, storage of iron in the form of ferritin as well as storage of vitamins A, D and B . The hepatocytes are efficient in uptaking blood bilirubin to conjugate it mainly with glucuronic acid and then excrete it in the bile. Potassium and sodium salts of the conjugated bile acids are also excreted into the bile. About 15% of the adult life erythropoietin is synthesized by the hepatic Kupffer cells and hepatocytes . The kidneys are dark-red, bean-shaped organs. The functional and structural unit of the kidney is the nephron. The kidneys are the main source (about 85%) of the circulating amount of erythropoietic hormone. The kidney is capable of carrying out several essential functions. These include: maintenance of body fluids volumes and their electrolytes within normal limits. It also participates in regulation of acid-base balance and blood pressure, excretion of the non-protein nitrogenous compounds, such as urea and uric acid, elimination of endogenous toxic waste agents. Through the kidneys the organism can get rid of hazardous compounds such as the endogenously produced creatinine and many metabolites of hormones as well as ingested and administered chemicals (e.g. drug). Formation of the active form of vitamin D takes place in the kidney. Gluconeogenesis, that is synthesis of glucose from non-carbohydrate source, is one of the kidney functions most especially under conditions of food deprivation and/or starvation. Although, there hasn't been any report on the harmful effect of the highly consumed plant on the body, it was known from laboratory testing, that high intake of

food supplements and additive from certain plants source may have deleterious effect on the body. In view of the reputed efficacies of this plant, the aim of this study was to elucidate some of the implications of *S. officinalis* on the histology of the kidney and liver in albino Sprague Dawley rats.

2. Materials and methods

2.1. Animal care

Ten rats (Sprague-Dawley strain) weighing between 160 - 190 g in weight were randomly assigned into two experimental groups designated as A and B. The rats in group A served as the control while the rats in group B served as the treatment group. The rats were treated in accordance with the "Guide for the Care and Use of Laboratory Animals" prepared by the National Academy of Sciences and published by the National Institutes of Health" (NIH, 1985). The rats were fed with standard rat chow obtained from J.D Adekomi Feed Mill, Ataoja Estate, Gbongan-Ibadan express Way, Osogbo, Osun State, Nigeria throughout the duration of the investigation. Fresh drinking water was supplied *ad libitum*.

2.2. Preparation of plant extracts

Fresh leaves of *S. officinalis* were air-dried and extracted according to the method of Adekomi (2010). A total of 1200 g of the dry leaf powder was extracted. The final yield (approximately 100 g) was a dark-brown sticky paste. This was stored at in a capped specimen bottle at 4.0°C in a refrigerator until used.

2.3. Animal treatment

The rats in the treatment group B were administered with 300 mg/kg body weight of the aqueous leaf extract of *S. officinalis* once daily using a sterilized flexible orogastric tube (Yakubu *et. al*, 2000), while the rats in the control group A were administered with equal volume of normal saline for 14d respectively. Twenty-four hour after the last administration, the rats were sacrificed using cervical dislocation. The kidney and liver were excised, fixed in Bouin's fluid and 10% formol saline respectively for 8 hour and were later processed for further routine histological study.

2.4. Histological procedure

After fixation in the respective fixatives, the histopathological study for the kidney and liver was carried out using the method of Carleton (1967). The organs of study were dehydrated through graded alcohol solutions, cleared in xylene, infiltrated and embedded in molten paraffin wax. Tissue blocks of 5µ thick sections were sectioned on a Leitz rotary microtome (Leitz 1512 Microtome). The tissues were subjected to H&E staining procedures and the histopathological examination was done with the aid of the Olympus binocular light research microscope (XSZ-107BN, No. 071771). The permanent photomicrograph of each slide was taken with a Kodak Digital Camera (Kodak Easyshare C183) for subsequent analysis.

3. Results

No gross alterations were observed in the morphology of the kidney and liver of the rats in the extract treated groups and those in the control groups twenty-four hours (24hrs) after the termination of experimental procedure. The kidney and liver (with all the component parts) of the rats in both the extract treated and control groups appeared morphologically normal. The histological preparations of kidney from the extract treated and control rats showed that the various histological segments of kidney tubules were well preserved. Abundant glomeruli, nephrons with interspersed blood capillaries were also clearly seen. Various regions of the kidney tubules appeared to be normal without any alteration in mesangial thickening or hyaline deposition. The renal parenchyma showed no evidence of distortion of any kind. It is evident at this magnification (i.e. x480) that the tubules constitute the bulk of the parenchyma with different shapes, diameters and staining intensity (Figs. 1 & 2).

When the sections obtained from the histological processing of the liver was viewed under the microscope it was observed that the sections conform to normal histological features. The sinusoids in the sections of the treated animals are devoid of occlusions and are not distorted. The extent of conformity to normal histological outline was observed to be higher in the extract treated groups compared with the control group (Figs. 3 & 4).

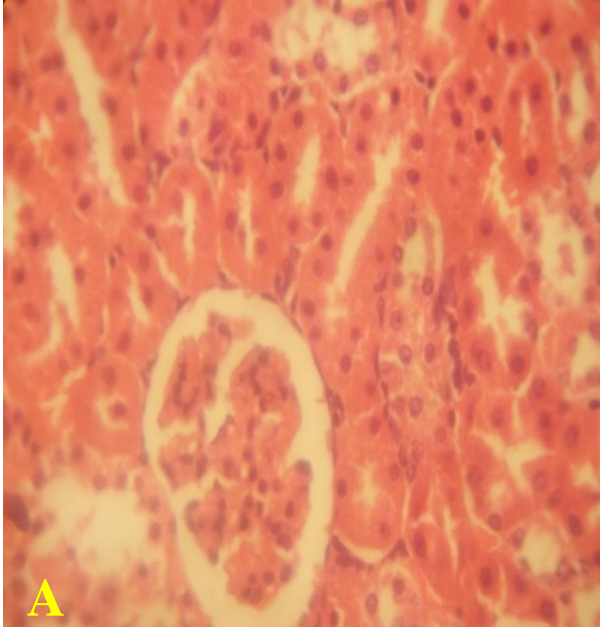


Fig. 1. the kidney section of the animals in the control group with normal histological profile (H&E x480).

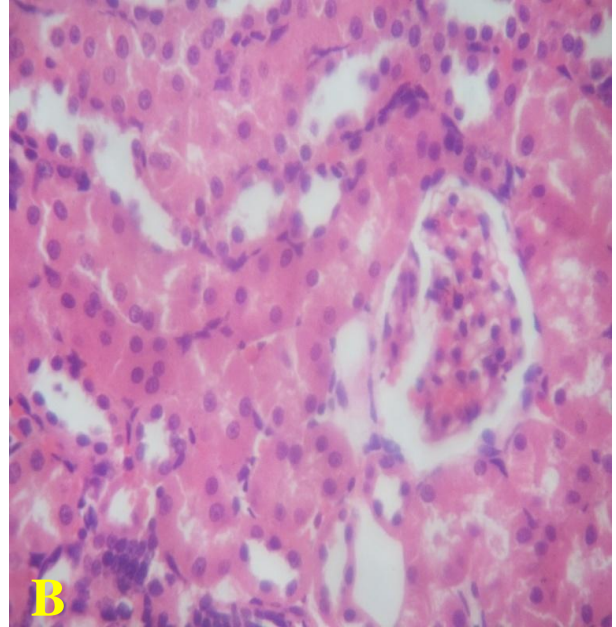


Fig. 2. the kidney section of the animals in the treated group with preserved histological profile (H&E x480).

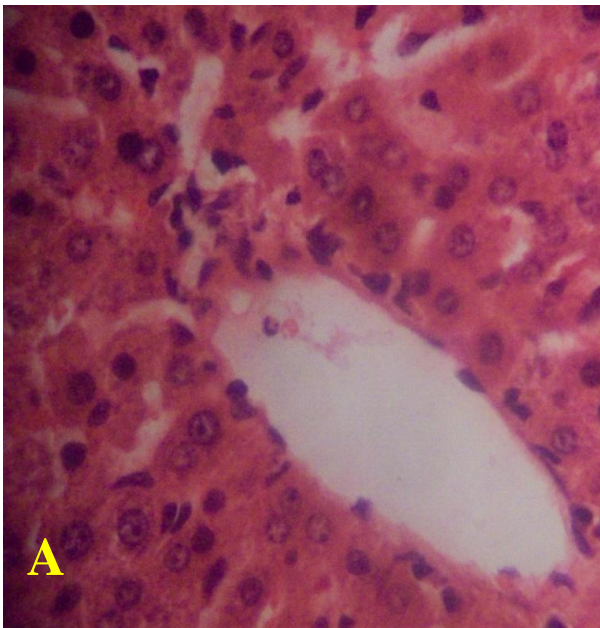


Fig. 5. Normal histological section of the liver of the rat in the control group (H&E x480).

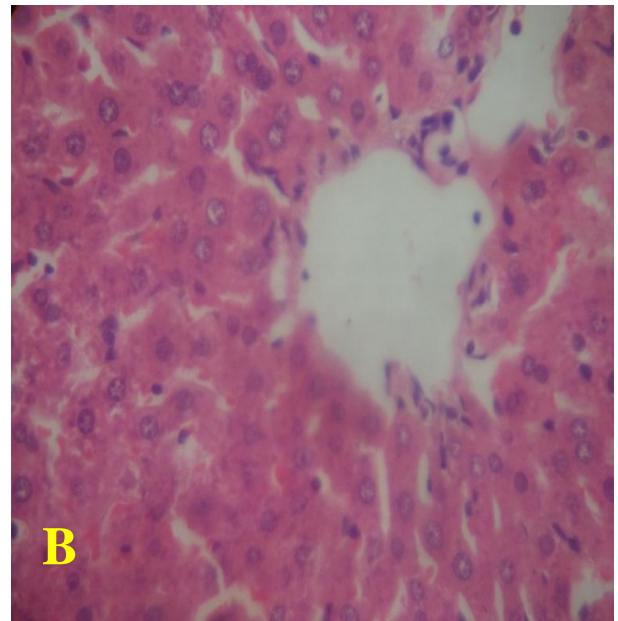


Fig. 4. Uncompromised histology of the liver of the rat in the treated group (H&E x480).

Using the Olympus binocular light research microscope (XSZ-107BN, No. 0717721), the histopathological assessment of the kidney and liver of the rats in the extract treated group displayed preserved histological profile as there were no alterations in the histoarchitectural profile of the kidney and liver of the rats. The histological sections obtained from the rats in the control group (Figs. 1-4) conformed to normal histological features.

4. Discussion

A 14d study on the effects of *S. officinalis* leaves on the kidney and liver was investigated to highlight the possible histopathological implications that could occur following its consumption. Using the Olympus binocular light microscope (XSZ-107BN, No. 071771), the results obtained from the sections of the kidney (extract treated rats) stained with hematoxylin and eosin (H & E) revealed that the plant extract is non-toxic and has no adverse effects on the histology of the kidney in Sprague Dawley rats. There were no observable cellular injury affecting the epithelial parenchyma and endothelial cell. The renal cortex was devoid of; tubular necrosis and glomerular hemorrhage. There were no histological derangement, degenerative changes, and apoptosis and/or necrosis of the cells within the convoluted tubules of the tubular system of the sections obtained from the extract treated rats. Also, the histology of the liver sections obtained from the rats treated with the leaf extract was also observed with the same model of microscope and it was observed that the histology of the liver was well preserved. There were no features of cellular degeneration, as the sinusoids in the sections of the extract treated rats were devoid of congestions, occlusions and were not erratically distorted. There were no necroses or oedema of the hepatocytes. There was no evidence of Mallory bodies in the liver parenchyma. The portal tracts were free of inflammations. The hepatocytes did not appear swollen, shrunken or distorted. The central veins were also intact.

Many herbal preparations have been known to exhibit renal tubular necrosis showing extensive interstitial fibrosis and severe tubular loss which are prominent in the outer cortex. Vanherweghem *et al.* (1993) and Mengs *et al.* (1982) showed that specific acid from herbal preparation are nephrotoxic in female Sprague Dawley rats which rapidly developed renal tubular necrosis and renal failure. The shapes of the cells within the convoluted tubules of the rats in the control group appeared cuboidal. These shapes were maintained in the extract treated sections after 14d of administration of the aqueous extract of *S. officinalis* leaves (Figs.1 & 2). This might enhance the proper functioning of the convoluted tubules in the exchange of fluids and ions, reabsorption of the components of the glomerular filtrate, control of acid base balance and more importantly, in urine concentration (Steven and Lowe, 2005).

According to Steven and Lowe, (2005), biochemical dysfunctions may result from impaired tubular functions as a result of failure of excretion of H and K ions. This then makes the blood to have an increase in the concentration of H ions (acidosis) and K ions (hyperkalemia), coupled with the retention of nitrogenous waste materials as a result of impairment in the function of the glomerulus, this may ultimately lead to renal failure (e.g. acute tubular necrosis, acute and chronic renal failure).

Response of cell to toxins has been conceptualized as one of the major cause of cell death and this may cause apoptotic death pathway within the kidney and liver cells (Waters, 1994). Genetic mechanism has also been implicated in cell death in that cell response to toxins occurring as controlled events involving cascade and/or succession of activated enzymes (Waters, 1994). In some instances, the kidney and/or the liver may be damaged as a result of oxidized agents known as free radicals generated in the body by the oxidation of nutrients derived from food substances and other chemical reactions taking place within the cells (Anderson, 2004).

Cellular degeneration in many organs of the body has been observed to be one of the major causes of cell death, which may occur either as apoptotic and necrotic cell death. These two form of cellular degeneration differs from each other morphologically and/or biochemically (Wyllie, 1980). Cell death occurring pathologically or accidentally is regarded as necrotic and could result from extrinsic implications and/or disturbances to the cell and these may include toxic or traumatic effects (Farber *et al.*, 1981). Processes involved in cellular necrosis which may lead to cell death include compromise and/or disruption of the structural and functional potentials of the various membranes in and within the cell. Necrosis of the cell is not induced by intrinsic stimuli to the cells as observed in programmed cell death, but by an abrupt environmental disturbances and deviation from the normal physiological conditions, factors and functions (Ito *et al.*, 2003). Gradual loss of the physiological functions of kidney and/or liver over time can lead to chronic diseases (e.g. acute tubular necrosis, acute and chronic renal failure). According to Guyton and Hall, (2000), one of the main functions of the kidney is to remove metabolic and/or toxic wastes and excess water from the body.

Dapar *et. al* (2007) suggested that, the estimation of tolerable doses of plant extract is of immense importance, in view of the large-scale human consumption of these herbs/plants either in culinary use or in managing or combating certain ailments and diseases and should be a matter of concern. The plant has been

reported to have many beneficial, culinary and medicinal properties and these could have been as a result of the chemical components of the plant.

It was observed that the plant has the potentials of enhancing the histological functions of the kidney and liver as the sections obtained from this study showed a better histological organization of the kidneys and livers of the extract treated rats. There is a need to determine if these observations in Sprague Dawley rats may be applicable to man.

5. Conclusion

The observations from this study suggested that *S. officinalis* was neither hepato-toxic nor was it nephro-toxic. Further studies should be directed towards isolating the specific biological and/or chemical component(s) of the plant responsible for the positive enhancing effects in order to standardize the plant preparation for maximum culinary and therapeutic benefit.

References

- Katzung, B.G., 2005. Basic and Clinical Pharmacology. 9th Edition, McGraw Hill Medical, New York.
- Bruneton, J., 1993. Plantes Médicinales: Phytochimie, Pharmacognosie. 2^{ème} Ed. Lavoisier, New York.
- Fola, A., 1993. Local medicinal plants and the health of the consumers. A paper delivered at the PSN/CF PCON organization workshop: in Clinical Pharmacy and Herbal Medicine. 9, 28-31.
- Agbor, A.G., Ngogang, Y.J., 2005. Toxicity of herbal preparations. Cam. J. Ethnobot. 1, 23-28.
- Agbor, A.G., Oben, J.E., Ngogang, J.Y., 2005. Haematinic activity of *Hibiscus cannabinus*. Afr. J. Biotechnol. 4 (8), 833-837.
- Prosper-Cabral et al., 2007. Phytochemical Studies and Antioxidant Properties of Four Medicinal Plants Used in Cameroon. Afr. J. Trad. CAM 4 (4). 495 – 500.
- Perry, N., Howes, M.J., Houghton, P., Perry, E., 2000. Why sage may be a wise remedy: effects of *Salvia* on the nervous system. In: Kintzios, S. (Ed.), In Sage. The Genus *Salvia*. Harwood Academic, The Netherlands, pp, 207– 232.
- Perry, N., Bollen, C., Perry, E.K., Ballard, C., 2003. *Salvia* for dementia therapy: review of pharmacological activity and pilot tolerability clinical trial. *Pharmacology, Biochemistry and Behavior* 75, 651– 659.
- Savelev, S.U., Okello, E.J., Perry, E.K., 2004. Butyryl-andacetyl-cholinesterase inhibitory activities in essential oils of *Salvia* species and their constituents. *Phytotherapy Research* 18, 315–324.
- Bartram, T., 1995. Encyclopaedia of Herbal Medicine, first ed. Grace Publishers, London.
- Kuang, P., Xiang, J., 1994. Effect of radix *Salviae miltiorrhiza* on EAA and dIAA during cerebral ischemia in gerbils: a microdialysis study. *Journal of Traditional Chinese Medicine* 14, 45–50.
- Moretti, M.D.L., Satta, M., Peana, A.T., 1997. A study on antiinflammatory and peripheral analgesic action of *Salvia sclarea* oil and its main components. *Journal of Essential Oil Research* 9, 199–204.
- Zupko, I., Hohmann, R., Falkay, G., Janicsak, G., Mathe, I., 2001. Antioxidant activity of leaves of *Salvia* species in enzyme-dependent and enzyme independent system of lipid peroxidation and their phenolic constituents. *Planta Medica* 67, 366–368.
- Clebsch, B., Carol, D.B., 2003. The New Book of Salvias. Timber Press, pp: 216, ISBN 9780881925609.
- The Herb Society of America; New Encyclopedia of Herbs & Their Uses, Deni Bown, New York: DK, 2001.
- National Institute of Health Guide for the Care and Use of Laboratory Animals: DHEW Publication (NIH), revised, Office of Science and Health Reports, DRR/NIH, Bethesda, USA, 1985.
- Adekomi, D.A., 2010. Madagascar periwinkle (*Catharanthus roseus*) Enhances Kidney and Liver Functions in Wistar Rats. Eur. J. Anat. 14, 111-119.
- Yakubu, M.T., Akanji, M.A., Oladiji, A.T., Olatinwo, A.O., Adesokan, A.A., Yakubu, M.O., et al., 2008. Effect of *Cnidioscolous aconitifolius* (Miller) I.M. Johnston leaf extract on reproductive hormones of female rats. Iran J Reprod Med, 6:149–55.
- Carleton, H., 1967. Carleton's histological technique. Oxford University Press, 4th Ed, pp. 33-280.
- Farber, J.L., Chein, K.R., Mittnacht, S., 1981. The pathogenesis of Irreversible cell injury in ischemia; Amer. J. Pathol. 102, 271-281.
- Guyton, A., Hall, J., 1996. Textbook of Medical Physiology, Philadelphia: WB Saunders Co.

- Stevens, A., Lowe, J., 2005. Human Histology; Chapter 12, p. 232. 3rd ed. Philadelphia: Elsevier Mosby. ISBN 0-3230-3663-5.
- Dapar, L.P.M., Aguiyi, C.J., Wannang, N.N., Gyang, S.S., Tanko, M.N., 2007. The Histopathologic Effects of *Securidaca longepedunculata* on Heart, Liver, Kidney and Lungs of Rats. Afr. J. Biotechnol. 6 (5), 591-595
- Ito, U., Sparts, M., Walker, J.R., Warzo, I., Experimental Cerebral Ischemia in Magolian Gerbils (1). Light microscope observations. Acta Neurophatology. USA. 32, 209-223.
- Waters, C.M., 1994. Glutamate induced apoptosis of striatal cells in rodent model for Parkinsonism. *Neuroscience*. 63, 1-5.