

**Short communication****An incidental case of perianal gland adenoma in a stray dog****L.G. Devi<sup>a</sup>, A. Choudhari<sup>b</sup>, N.D. Singh<sup>c,\*</sup>, H.S. Banga<sup>c</sup>, P.D. Gadhave<sup>c</sup>**<sup>a</sup>Department of Pathology, AIIMS, New Delhi, India<sup>b</sup>Veterinary Officer, People for Animal, New Delhi, India<sup>c</sup>Department of Vet. Pathology, COVS, GADVASU, Ludhiana

\*Corresponding author; Department of Vet. Pathology, COVS, GADVASU, Ludhiana

## ARTICLE INFO

## ABSTRACT

*Article history:*

Received 08 August 2012

Accepted 10 August 2012

Available online 14 August 2012

*Keywords:*

Perianal gland

Adenoma

eosinophilic cytoplasm reserve cells

A naturally dead stray dog suffering from perianal gland adenoma was reported here. On post-mortem examination 5 cm large ulcerated mass was found at the base of tail partially obstructing anal opening. Histologically the tumour comprised of large round neoplastic cells with round centrally located nuclei, eosinophilic cytoplasm and well distinct cell borders which were surrounded by single layered hyperchromatic reserve cells. The neoplastic mass showed encapsulation by fibrous tissue and trabeculae in between. The mass was supposed to be affecting normal defecation process leading to constipation and subsequent toxemia leading to death of the dog.

© 2012 Sjournals. All rights reserved.

**1. Introduction**

Perianal glands are non-secretory abortive sebaceous glands found near the anus of dog but also on prepuce, tail, hind limbs and trunk (Maita and Ishida, 1975). Secretions of these glands are useful in making territory marks. The tumour arising from these glands are predominantly benign (Gross *et al.*, 1992) or sometimes malignant (Vail *et al.*, 1990). These tumours may affect the normal bowel movements and hence defecation process leading to health problems in dog. The occurrence is mostly reported in the domestic dogs due to well awareness of the dog owners but they go unnoticed in stray dogs. The present case reports such incidence of perianal gland tumour in stray dog which died naturally and most probably due to the complication of the tumour.

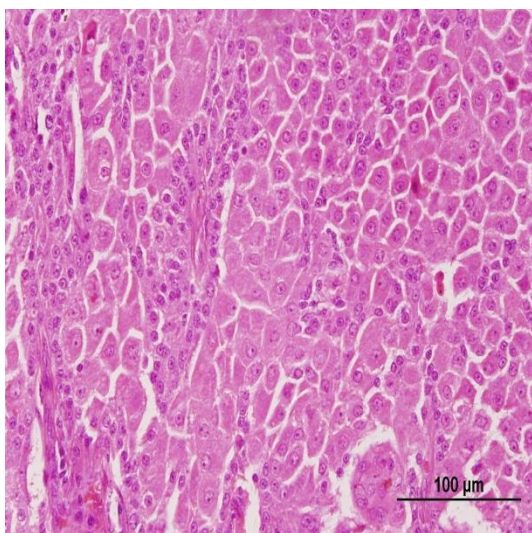
## 2. Materials and methods

A nondescript adult male dog died naturally was presented by an animal lover to PFA, Delhi. The carcass was in advanced autolytic stage with enlarged abdomen. A through post-mortem examination was done and gross observations were noted. The relevant organs were collected for the routine histopathological examination in 10% neutral buffered formalin. The fixed samples were then processed as per the standard protocols of Bancroft and Gamble (2008).

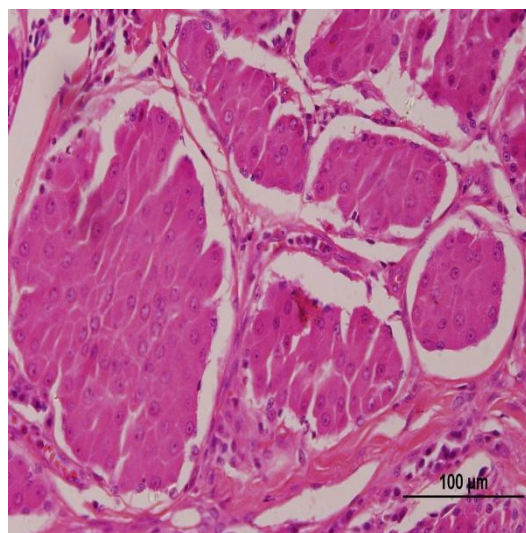
## 3. Results and discussion

Gross examination of the carcass revealed 5 cm large ulcerated swelling at the base of tail. On palpation enlarged mass was also felt inside the anus which was partially obstructing the anal opening. The intestine was full of fecal material. Generalized congestion and haemorrhages were also observed on vital organs. The swelling was suspected to be a tumour. Microscopically, the tumour was showing discrete bundles of large, round neoplastic cells with well distinct cell borders. The nucleus of these cells were centrally located and surrounded by eosinophilic cytoplasm which resembled hepatic tissue and hence the name hepatoid gland (Fig. 1). The growth of these cells was well encapsulated by fibrous tissue and trabecular structure was evident (Fig.2). Reserve cells showed hyperchromacia and little cytoplasm were present in single layers at periphery of hepatoid cells and also in between the lobes (Fig.3). Anisocytosis was minimal and mitotic figures were rarely seen in both the hepatoid and reserve cells. Areas of keratinization were observed occasionally in the section. The ulcerated epidermis with presence of haemorrhage was also evident. Other organs like liver, heart and lung revealed generalized congestion and haemorrhages microscopically. Depending upon the histopathological features the tumour was diagnosed as hepatoid gland adenoma. These tumours most commonly occurred in male dogs because of their association with androgen a male sex hormone as compared to the females (Kaldrymidou *et al.*, 2002). Sanja (2005) reported high prevalence of hepatoid adenoma in non castrated adult male dogs. The treatment of perianal adenomas was suggested as castration and surgical excision (Wilson and Hayes, 1979). But Vail *et al.*, (1990) reported that the castration alone is not sufficient to cause regression of these tumours. Therefore Pasini *et al.*, (2006) suggested that besides castration and surgical excision of the tumour, anti hormonal treatment could be of great use in treating such tumours.

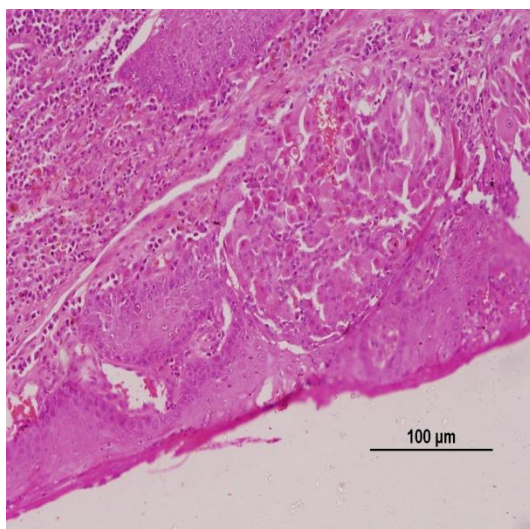
In the present case the stray dog was non-castrated and due to the old age probably got predisposed to the perianal gland tumour which was evident histopathologically. The growing mass possibly affected the normal defecation process leading to constipation and subsequent toxemia leading to death of the dog.



**Fig. 1.** Large round neoplastic cells with centrally located nuclei and eosinophilic cytoplasm. H&E X 10.



**Fig. 2.** Encapsulated neoplastic cell mass with trabeculae in between. H&E X 10.



**Fig. 3.** Hyperchromatic reserve cells forming single layers at periphery of hepatoid cells and also in between the lobes. H&E X 10.

#### 4. Conclusion

Japanese quail, despite their small body size, have an important place in commercial production because of their high egg and meat production capacity. In addition, many producers want to obtain heavier quails since small quails are not preferred by consumers, which extend the rearing period. However, it has been confirmed that most of the weight increases are due to abdominal fat deposition when the optimal slaughtering age of the Japanese quail is exceeded (Toelle *et al.*, 1991). This situation causes significant economic losses to producers and results in lesser quality products for consumers. However, it is possible to attain positive results in a short period of time by applying suitable breeding strategies to increase carcass weight and quality. Reaching sexual maturity, fattening occurs more rapidly and extensively in females due to female hormones resulting in a higher weight compared to the male quails. Conclusively, successful breeding study, genetic parameters of the selected traits should be correctly estimated and suitable breeding programmes is planned.

#### References

- Bancroft, J.D., Gamble, M., 2008. Theory and Practice of Histological Techniques. 6<sup>th</sup> edn. Churchill Livingstone, Elsevier, China.
- Gross, T.L., Ihrke, P.E., Walder, E.J., 1992. Veterinary Dermatopathology: a Macroscopic and Microscopic Evaluation of Canine and Feline Skin Disease. Mosby-Yearbook, St. Louis, MO, USA, pp 381-385.
- Kaldrymidou, H., Leontides, L., Koutinas, A.F., Saridomichelakis, M.N., Karayannopoulou, M., 2002. Prevalence, distribution and factors associated with the presence and the potential for malignancy of cutaneous neoplasms in 174 dogs admitted to a clinic in northern Greece. *J. Vet. Med. A.* 49, 87-91.
- Maitam, K., Ishida, K., 1975. Structure and development of the perianal gland of the dog. *J. Vet. Sci.* 37, 349-356. <http://www.ncbi.nlm.nih.gov/pubmed/11958472>
- Pisani, G., Millanta, F., Lorenzi, D., Vannozzi, I. Poli, A., 2006. Androgen receptor expression in normal, hyperplastic and neoplastic hepatoidglands in the dog. *Res. Vet. Sci.* 8 1(2), 231-236. <http://www.ncbi.nlm.nih.gov/pubmed/16427103>
- Sanja, A.K., Kukolj, V., Marinkovic, D., Milijana, K., 2005. Retrospective study of canine epithelial and melanocytic tumors. *Acta Vet-Beograd.* 55, 319-326. <http://www.ncbi.nlm.nih.gov/pmc/articles/PMC2868128/>

- Vail, M., Withrow, S.J., Schwarz, P.D., Powers, B.E., 1990. Perianal adenocarcinomas in the canine male: a retrospective study of 41 cases. *J.A.A.H.A.* 26, 329-334.
- Wilson, G.P., Hayes, H.M., 1979. Castration for treatment of perianal gland neoplasms in the dog. *J. Am. Vet. Med. Assoc.* 174, 1301-1303.