

Contents lists available at Sjournals



Journal homepage: [www.Sjournals.com](http://www.Sjournals.com)



**Short communication**

## Use of ultrasonography for pregnancy diagnosis in red Sokoto goats

**B.O. Omontese<sup>a,\*</sup>, P.I. Rekwot<sup>b</sup>, I.U. Ate<sup>a</sup>, J.S. Rwuan<sup>a</sup>, H.J. Makun<sup>c</sup>, R.A. Mustapha<sup>a</sup>, M. Lawal<sup>d</sup>**

<sup>a</sup>Department of Theriogenology and Production, Faculty of Veterinary Medicine, Ahmadu Bello University, Zaria, Nigeria.

<sup>b</sup>Artificial Insemination Unit, National Animal Production Research Institute, Ahmadu Bello University, Zaria, Nigeria.

<sup>c</sup>Small Ruminant Research Programme, National Animal Production Research Institute, Ahmadu Bello University, Zaria, Nigeria.

<sup>d</sup>Department of Surgery and Radiology, Faculty of Veterinary Medicine, Ahmadu Bello University, Zaria, Nigeria.

\*Corresponding author; Department of Theriogenology and Production, Faculty of Veterinary Medicine, Ahmadu Bello University, Zaria, Nigeria

### ARTICLE INFO

### ABSTRACT

*Article history:*

Received 26 November 2012

Accepted 18 December 2012

Available online 29 December 2012

*Keywords:*

Ultrasonography  
Pregnancy diagnosis  
Conception  
Red Sokoto

The present study was conducted to diagnose pregnancy 30 days following estrus synchronization and natural mating using transabdominal ultrasonography and to compare the traditional use of non return rates of estrus with pregnancy diagnosis by day 30 using transabdominal ultrasonography in "Red Sokoto goats" of Nigeria. Forty nine (n=49) Red Sokoto does were treated with fluorogestone acetate sponges (FGA-30) for 15 days. At the end of progestagen treatment, does received i.m 200 IU equine chorionic gonadotrophin (eCG) concurrent with progestagen removal. Does were mated naturally using proven sexually active bucks in the ratio 1 buck to 10 does. Measurement of non-return rates of estrus was evaluated 21 to 30 days following estrus and natural mating. Pregnancy rate was determined on day 30 following estrus and natural mating using a real time B-mode ultrasound scanner equipped with a 3.5 MHz probe. Non return rate of estrus (conception) was compared with pregnancy rate using ultrasonography. Conception rate by measurement of non return rate of estrus by day 30 was 87.7 % (43/49). An 85.7 % (42/49) pregnancy rate was obtained at day 30 of gestation using

ultrasonography. Conceptus in pregnancy fluid was visible in 100% cases between 30 and 35 days of gestation. From the knowledge of the authors, this is the first report of pregnancy diagnosis using ultrasonography in Red Sokoto goats of Nigeria.

© 2012 Sjournals. All rights reserved.

---

## 1. Introduction

Nigeria ranks among the top six countries of the world in goat meat production (Dubeuf *et al.*, 2004) and the Red Sokoto goats are the dominant and most widely distributed in the northern Savannah belts of Nigeria (Gall, 1996). In recent times, ultrasonography plays leading roles in pregnancy determination, diagnoses associated with uterine and ovarian infections. In addition, ultrasonography provides added benefits such as fetal sexing and early embryonic detection. From a research standpoint, ultrasound has given us the ability to visually characterize the uterus, fetus, ovary, corpus luteum, and follicles (Beal *et al.*, 1992). Some authors have employed the use of ultrasonography in estimating gestational age (Santigo *et al.*, 2005), determination of first pregnancy (Amer, 2007), studying morphological features of ovaries (Nwaogu and Okolie, 2009), measurements of foetal parameters (Lee *et al.*, 2003), *Corpora lutea* diameter (Bukar *et al.*, 2012), examination of the mammary gland (Kiossis *et al.*, 2009; Ślosarz *et al.*, 2010; Fasulkov, 2012), diagnosis of late embryonic and fetal death (Yotov, 2012) and omasum (Braun and Jacquat, 2011). Ultrasonography is a non-invasive and it plays valuable roles in the diagnosis of various physiological and pathological conditions of the reproductive organs of ruminants (Dimitrov *et al.*, 2002; Kahn, 2004; Yotov, 2005; Yotov *et al.*, 2008). Ultrasonography has enabled monitoring of the pattern of antral follicular development in cattle and goats and thus has increased the understanding of the dynamics of follicular development, growth, dominance and atresia as well as the ovulatory process (Aerts and Bols, 2010).

Early diagnosis of pregnancy and fetal sexing using ultrasonography enhances reproductive management on farms and improves the commerce of pregnant animals (Reichenbach *et al.*, 2004; Santos *et al.*, 2004). It is important in livestock production to make culling/rebreeding decisions, for food allotment, and for clinical and research purposes. Examination of the goat for pregnancy may be done as part of a reproductive herd health program or may simply be requested by the pet goat owner who would like to know the pregnancy status of his or her doe (Dawson, 1999). A reliable technique for early detection of pregnancy would allow early culling or rebreeding of barren does (Dawson, 1999). Traditional methods for pregnancy diagnosis in small ruminants are by abdominal palpation/balottement and noting udder enlargement. However, these methods are applicable only in late gestation. Currently, transabdominal ultrasonography has been used with great deal of accuracy as a means for pregnancy diagnosis and estimation of fetal numbers in deer (Revol and Wilson, 1991), reindeer (Vahtiala *et al.*, 2004), sheep (Garcia *et al.*, 1993) and goat (Martínez *et al.*, 1998; Gonzalez *et al.*, 2004) especially in developed countries. However information in this regard is meager on sheep and goats in a developing country like Nigeria. The Red Sokoto goat accounts for over 70 % of the population of goats in Nigeria (RIMS, 1992). The present study was designed: (i) to diagnose pregnancy using transabdominal ultrasonography 30 days following estrus synchronization and natural mating, and (ii) to compare non return rates of estrus following estrus synchronization and natural mating with pregnancy diagnosis by day 30 using transabdominal ultrasonography in "Red Sokoto goats" of Nigeria.

## 2. Materials and methods

### 2.1. Animals

This study was conducted on forty-nine (n=49) Red Sokoto does, aged 1.5 – 2 years, maintained at the Small Ruminant Research Programme (SRRP) of the National Animal Production Research Institute, Shika, Ahmadu Bello University, Zaria, Nigeria. NAPRI is located in the Northern Guinea Savannah zone of Nigeria between latitude 11 °N and 12 °N and between longitude 7 °E and 8 °E at an elevation of 650 m above sea level with an average annual maximum and minimum temperature of 31.0 ± 3.2 °C and 18.0 ± 3.7 °C respectively. Shika has an average annual rainfall of 1100 mm usually lasting from May to October with a mean relative humidity of 72 % while the dry

season lasts from November to April with mean daily temperatures ranging from 15 – 36 °C and mean relative humidity of between 20 – 37 % (Rekwot *et al.*, 1998). Does were fed *Digitaria smutsii* (wooly finger grass) hay; concentrate supplement (0.5 kg/day), and water was provided *ad libitum*. Does were synchronized using intravaginal progestagens (Flurogesterone acetate sponges) for 14 days. Following removal of sponges and intramuscular administration of equine chorionic gonadotrophin (200 IU), breeding (flock mating) was carried out with five proven fertile bucks for five days. All procedures were approved by the Animal Ethic Committee of the university.

## 2.2. Conception rate

Daily observations of mated does were made 19 to 22 days after natural mating to evaluate conception rates using measurement of non return to estrus using tested sexually active bucks. Does that returned to estrus were recorded, separated and rebred by a fertile buck.

## 2.3. Pregnancy diagnosis using ultrasonography

A real time B-mode ultrasound scanner equipped with a 3.5 MHz probe (Aloka SSD-500, Aloka Co., Ltd., Japan) was used for diagnosing pregnancy. Food and water were withheld overnight for 12 hours before scanning early in the morning. Scanning was performed on the shaved hair-less inguinal region of the does. The does were gently restrained by two persons on an examination table while the hind legs of the does were folded up at the time of scanning for proper placement of the probe. An ultrasound coupling gel was applied each time to the probe to develop good contact and to remove air between probe and animal skin. This was performed on day 30 following mating. Forty-nine (n=49) Red Sokoto does were imaged once to determine pregnancy. A doe was designated pregnant by imaging apparent conceptus (anechoic, elongated structure) within uterine fluid (Figure 1). Pregnancy diagnosis using ultrasonography was compared with non return rate of estrus at day 30.

## 3. Results and discussion

Forty-three (n=43) of the forty-nine (n=49) does mated did not return to estrus after a 30 day period of observation giving a conception rate of 87.7 % (Table 1). This is similar to the 88.5 % reported by Jatau, (2002) in Red Sokoto goats treated with double injection protocol of prostaglandin following natural mating and the reports of Akusu (2003) in West African Dwarf goats. On the other hand, forty-two (n=42) does were detected pregnant using ultrasonography by day 30 to 35 of gestation resulting in 85.7 % pregnancy rate (Table 1). This is lower than but close to the 87.7 % non return rate obtained for the same mated does. This lower pregnancy rate may be due to embryonic mortality that may have resulted following failure to establish and maintain pregnancy. At day 30 to 35 of gestation in Red Sokoto does, ultrasonographic observations of the echoic conceptus in anechoic pregnancy fluid was noted. This is similar to the report of Anwar *et al.* (2008) in Balkhi sheep by 30 days of gestation but less than the 100 % reported by Santos *et al.* (2006) in Boer goats using transrectal ultrasonography between day 45 and 60 of gestation. The filled urinary bladder in most cases was visible close to the uterine lumen as shown in figure A.

**Table 1**

Conception (Non return) and pregnancy rate in Red Sokoto does by transabdominal Ultrasonography at day 30 after buck introduction following estrus synchronization

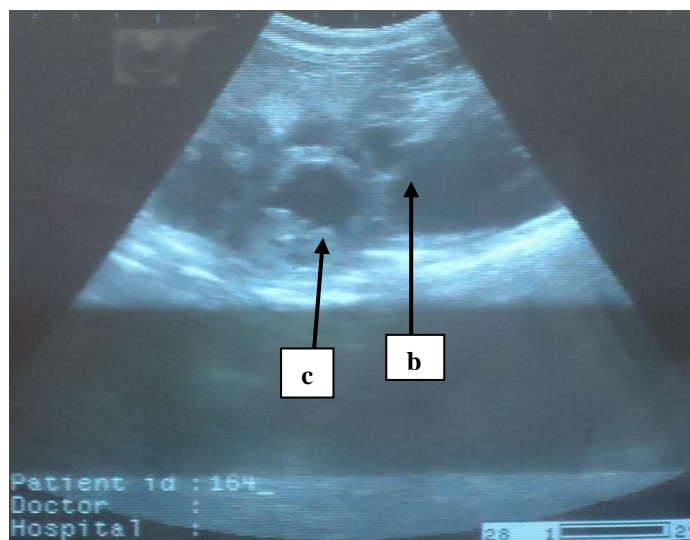
<b>Red Sokoto does</b>	
Number of does (n)	49
Conception (Non return) Rate (%)	43/49 (87.7)
Return Rate (%)	6/49 (12.3)
Pregnancy Rate (%)	42/49 (85.7)
Non Pregnant (%)	7/49 (14.3)

KEY

( ) = Percentage

Although the accuracy of pregnancy diagnosis in this study was not assessed since only a single ultrasound scan was performed, an accuracy of pregnancy detection of 80% at day 31-35 has been reported by Anwar *et al.*

(2008) in Balkhi sheep of Pakistan while a 95 % accuracy in the diagnosis of pregnancy from 40 to 50 days has been reported using a 3 MHz probe (Fowler and Wilkins, 1984). It is concluded that conception rate may be evaluated using measurement of non return rates of estrus in flocks where ultrasound diagnosis of pregnancy cannot be afforded due to extra production cost required and that pregnancy diagnosis in Red Sokoto does may be achieved at day 30 of gestation by transabdominal ultrasonography using a 3.5 MHz probe.



**Fig. 1.** Ultrasonographic image of the Red Sokoto goat conceptus on day 30 of pregnancy using a 3.5 MHz transabdominal probe.

Day 30: Conceptus (c) in pregnancy fluid. Filled urinary bladder (b) visible close to uterine lumen.

### Acknowledgements

We are thankful to herdsmen and the Director, NAPRI for permission to publish this work.

### References

- Aerts, J.M.J., Bols, P.E.J., 2010. Ovarian follicular dynamics. A review with emphasis on the bovine species. Part II: Antral development, exogenous influence and future prospects. *Reprod. in Dom. Anim.* 45, 180-187.
- Akusu, M.O., 2003. Fertility of West African Dwarf goat following estrus synchronization with PGF<sub>2α</sub>. In: *Reproductive performance of goats for Maximum Animal Production in Nigeria. Inaugural Lecture, 2002/2003, University of Ibadan, Nigeria, 42 - 45*
- Amer, H.A., 2007. Determination of first pregnancy and foetal measurements in Egyptian Baladi goats. *Veterinarski Italiana* 44, 429-437.
- Anwar, M., Riaz, A., Ullah, N., Rafiq, M., 2008. Use of ultrasonography for pregnancy diagnosis in Balkhi sheep. *Pakistan Vet. J.* 28(3), 144-146.
- Beal, W.E., Perry, R.C., Corah. L.R., 1992. The use of ultrasound in monitoring reproductive physiology of beef cattle. *J. of Anim. Sci.* 70, 924-929.
- Braun, U., Jacquat, D., 2011. Ultrasonography of the omasum in 30 Saanen goats. *BMC Vet. Res.* 7, 11-19.
- Bukar, M.M., Rosnina, Y., Ariff, O.M., Wahid, H., Khan, G.K.M.A., Yimer, N., Dhaliwal, G.K., 2012. Corpora lutea diameter, plasma progesterone concentration and follicular development in PGF<sub>2α</sub> and CIDR estrus synchronized goats. *Pak. Vet. J.* 32(2), 216-220.
- Dawson, L.J., 1999. *Pregnancy Diagnosis in Goats. Pages 97-103 in Proc. 14th Ann. Goat Field Day, Langston University, Langston, OK*
- Dimitrov, M., Vassilev, N., Georgiev, P., Ivanov, I., Yotov, S., 2002. Ultrasonographic assessment of early pregnancy in animals. *Bulgarian J. of Vet. Med.* 5, 167-178.

- Dubeuf, J., Morand-Ferh, P., Rubino, R., 2004. Situation, changes and future of goat industry around the world. *Small Rumin. Res.* 52, 165-173.
- Fowler, D.G., Wilkins, J.F., 1984. Diagnosis of pregnancy and number of fetuses in sheep by real time ultrasound imaging. I. Effects of number of fetuses, stage of gestation, operator and breed of ewe on accuracy of diagnosis, *Livestock Prod. Sci.* 11, 437-450.
- Fasulkov, I.R., 2012. Ultrasonography of the mammary gland in ruminants: A review. *Bulgarian J. of Vet. Med.* 15 (1), 1-12.
- Gall, C., 1996. Red Sokoto goats In: Goat Breeds of the World. Bohler Verlag. Würzburg Germany, pp. 55-56.
- Garcia, A.M.K., Neary, G., Kelly, R., Pierson, R.A., 1993. Accuracy of ultrasonography in early pregnancy diagnosis in the ewe. *Theriogenology* 39, 847-861.
- Gonzalez, F.C., Batista, M., Rodriguez, N., Alamo, D., Sulon, J., Beckers, J.F., Gracia, A., 2004. A comparison of diagnosis of pregnancy in the goat via transrectal ultrasound scanning, progesterone and pregnancy-associated glycoprotein assays. *Theriogenology* 62, 1108-1115.
- Jatau, J.D., 2002. Oestrus response and conception rate Red Sokoto Goats following estrus synchronization with prostaglandin F<sub>2α</sub>. *H.N.D thesis. National Veterinary Research Institute, Vom, Plateau State, Nigeria.*
- Kahn, W., 2004. Ultrasonography in sheep and goats. In: *Veterinary Reproductive Ultrasonography*, Schlutersche Verlagsgesellschaft GmbH & Co., Hannover, pp. 187-210.
- Kiossis, E., Brozos, C.N., Papaioannou, N., Tzanidakis, N., Boscos, C., 2009. Endoscopic and histopathological findings of teats in dairy ewes. *Small Rumin. Res.* 87, 70-75
- Lee, Y., Lee, O., Cho, J., Shin, H., Choi, Y., Shim, W., Choi, W., Shin, H., Lee, D., Shin, S., 2003. Ultrasonic measurement of foetal parameters for estimation of gestational age in Korean black goats. *J. of Vet. Med. Sci.* 67, 497-502.
- Martínez, M.F., Bosch, P., Bosch, R.A., 1998. Determination of early pregnancy and embryonic growth in goats by transrectal ultrasound scanning. *Theriogenology* 49, 1555-1565.
- Nwaogu, I.C., Okolie, I.P., 2009. Studies on morphological features of foetal and adult ovaries in Kano brown goats. *Anim. Reprod. Sci.* 115, 58-65.
- Reichenbach, H.D., Santos, M.H.B., Oliveira, M.A.L., Meinecke-Tillmann, S., Bürstel, D.M., 2004. Sexagem fetal na cabra e na ovelha por ultra-sonografia. In: Santos MHB, Oliveira MAL, Lima PF (Eds.). *Diagnóstico de gestação na cabra e na ovelha*. São Paulo, Brasil: Varela. pp.117-136.
- Rekwot, P.I., Oyedipe, E.O., Barje, P.P., Rwuuan, J.S., 1998. Factors affecting the reproductive performance of cattle in Nigeria. *Nigerian Vet. J.* 19, 66-77.
- Revol, B., Wilson, P.R., 1991. Foetal ageing in farmed red deer using real-time ultrasonography. *Anim. Reprod. Sci.* 25, 241-253.
- RIMS 1992. Nigerian livestock resources survey report by resource inventory and management (RIM) to Federal Department of Livestock and Pest Control Services (FDLPCS), Abuja, Nigeria.
- Santiago, M.J., Gonzalez, B.A., Gomez, B.A., Toledano, D.A., Lopez, S.A., 2005. Prediction of gestational age by transrectal ultrasonographic measurements in the mouflon (*Ovis gmelini musimon*). *J. of Zoology and Wildlife Med.* 36, 457-462.
- Santos, M.H.B., Oliveira, M.A.L., Lima, P.F., Moraes, E.P.B.X., Chalhoub, M., Bicudo, S.D., 2004. Diagnóstico de gestação por ultra-sonografia de tempo real. In: Santos, MHB, Oliveira, MAL, Lima, PF (Eds.). *Diagnóstico de gestação na cabra e na ovelha*. São Paulo, Brasil: Varela. p.97-116.
- Santos, M.H.B., Moura, R.T.D., Chaves, R.M., Soares, A.T., Neves, J.P., Reichenbach, H.D., Lima, P.F., Oliveira, M.A.L., 2006. Sexing of Boer goat fetuses using transrectal ultrasonography. *Anim. Reprod. Sci.* (3) 3, 359-363.
- Ślosarz, P., Wojtowski, J., Bielińska, S., Frąckowiak, A., Ludwiczak, A., Krzyśewski, J., Bagnicka, E., Strzalkowska, N., 2010. Machine induced changes of caprine teats diagnosed by ultrasonography. *Afr. J. of Biotech.* 9, 8698-8703.
- Vahtiala, S., Sakkinen, H., Dahl, E., Eloranta, E., Beckers, J.F., Ropstad, E., 2004. Ultrasonography in early pregnancy diagnosis and measurements of fetal size in reindeer (*Rangifer tarandus tarandus*). *Theriogenology* 61, 785-795.
- Yotov, S., 2005. Diagnostics of early pregnancy in Stara Zagora dairy sheep breed. *Bulgarian J. of Vet. Med.*, 8, 41-45.

- Yotov, S., Wehrend, A., Vassilev, N., Georgiev, P., Lottner, S., Antonov, A., Atanasov, A., 2008. Ultrasonographic fetal sex determination in sheep depending on gestational age and fetal position (Abstract). *Reprod. in Dom. Anim.* 43 (1), 35-39.
- Yotov, S., 2012. Ultrasound Diagnostics of Late Embryonic and Foetal Death in Three Sheep Breeds. *J. of Vet. Adv.* 2(3), 120-125.